

2 Message from the Minister of Health

Minister's Office: 256-041-340871
Telephone: General Lines: 256-041-340874/
231563-9
Fax: 256-041-231585

IN ANY CORRESPONDENCE ON THIS SUBJECT PLEASE QUOTE No. **ADM 178/43**



Office of the Minister of Health
P.O. Box 7272,
Kampala
Uganda

FORWARD

Health indices in Uganda, like most developing countries, are still very poor. Maternal Mortality and Infant Mortality Rates have remained at 506 per 100,000 and 88 per 1,000 live births respectively over an unacceptably long period of time. Most deliveries occur outside health units and are unattended by skilled caregivers. For infants who survive, it is imperative they grow into healthy, productive and useful citizens.

Congenital abnormalities further reduce the chances of survival and affect productivity of children who survive the numerous killer childhood illnesses. Clubfoot is a common congenital abnormality in our communities. Unattended, it leads to permanent disabilities and social downgrading of patients. The situation is further compounded by lack of detection and treatment at birth.

This effort to reduce morbidity and disability associated with clubfoot is an important contribution to the economic growth of the country and improvement of the social and economic status of affected individuals. I welcome the Uganda Sustainable Clubfoot Care Project to address the burden of clubfeet in the country. I highly appreciate the public health approach to clubfoot problems and their management in Uganda. This will not only have the benefit of correction of the clubfoot but also improve neonatal and childhood services that help children grow and lead productive lives.

This manual on Ponseti Clubfoot Management is a landmark effort to implement the strategy of reducing the long term effects of this condition. The manual is practical, easy to use, and very rich in scientific information. I am sure it will be very useful to all those involved in clubfoot detection, management and rehabilitation programs, especially doctors, orthopaedic officers, orthopaedic technicians, nurses, and midwives. They will find the manual very useful and handy in their work on clubfoot.

I would like to thank all those who contributed to the production of this manual. I particularly thank Professor Pirani of the University of British Columbia, all the donor agencies who gave financial support, the staff of the Ministry of Health, Makerere University and the management of the Uganda Sustainable Clubfoot Care Project for this excellent manual.

I highly recommend this manual to all those associated with care of infants, especially those with clubfeet.

A handwritten signature in black ink that reads 'S. O. Mallinga'.

Dr. Stephen O. Mallinga
MINISTER OF HEALTH



Project Director's Message

The congenital clubfoot is the most common serious birth defect of human bones and joints. More than fifteen hundred children are born with clubfeet in Uganda each year. Left untreated, the foot remains twisted inwards and becomes painful. The walking child bears weight on the thin skin on the top of the foot. Deformity leads to the downward spiral of disability, dependency, and demoralization. Disabled individuals are rarely productive or valued members of society. Their needs add to the burdens of their families and communities and are a significant cause of poverty.

Professor Ignacio Ponseti's method of nonsurgical treatment of the congenital clubfoot has been shown by Macharia to be effective in Uganda. It is now the treatment of choice advocated by the Ministry of Health, the Association of Surgeons of Uganda, the Uganda Nurses and Midwives Council, the Medical Schools at Makerere University and Mbarara University of Science and Technology, and the Paramedical Schools at Mulago Hospital.

The Uganda Sustainable Clubfoot Care Project (the Uganda Project), is a Canadian International Development Agency funded collaborative work. Its goal is to make Ponseti treatment available to all affected infants born in Uganda in a timely, safe, effective, and sustainable manner. The project's methodology is to build capacity in two areas:

1. In Uganda's schools of healthcare (medical, nursing, and paramedical training schools) to teach clubfoot detection and Ponseti treatment.
2. In Uganda's healthcare institutions (hospitals and clinics where children are seen) to detect clubfeet at birth and treat the condition with the Ponseti Method.

The authors' intent is to provide one easily digestible source for all core material on clubfoot detection and treatment by the Ponseti Method for students in Uganda's medical, nursing and paramedical schools as well as for healthcare workers looking after infants in Uganda's healthcare institutions.

The Project will print and distribute ten thousand copies of this booklet to Uganda's healthcare schools and institutions. The authors hope that this will lead to increased awareness of foot deformities by healthcare workers, routine recognition of foot deformities at birth, and early referral to and effective treatment by trained staff at a network of clubfoot clinics across Uganda. Effective treatment corrects the deformity. Affected children will be more likely to grow up following the same life trajectory as any other child in Uganda. Clubfeet will be less likely to cause disability and poverty in Uganda.

Even though this teaching manual is by Ugandans and for Ugandans, its message is appropriate in many other developing nations facing the same burdens and restraints. The authors plan to make the guide widely available.

This work is the fruit of many people and many organizations working towards a single goal. We would like to thank all. This publication would not have been possible without them.

Shafique Pirani, MD
2008



Edward Naddumba, MD
2008

QUICK FIND TABS

Your core material is identified by the tab color.

EVERYONE

PARENTS

NURSES

ORTHOPAEDIC
OFFICERS

MEDICAL
OFFICERS

SURGEONS

ORTHOPAEDIC
TECHNOLOGISTS

4 Editor's Note

Editor's Note

This publication is the product of the efforts of many individuals and organizations. It brings together elements of Dr. Pirani's manual, Mr. Steenbeek's publication on clubfoot brace design, the Global HELP Organization's *Ponseti: Clubfoot Management* book, and new material gathered in Uganda and from experience in clubfoot management worldwide.

The design of this publication utilizes features developed for other HELP publications that are colorful, graphic, and engaging, and is presented efficiently and compactly. The publication was created entirely by digital software, simplifying translations and the addition of new material.

We intended that the publication would provide the core information for all healthcare providers who contribute to clubfoot management. This publication includes elements useful to all providers.

A study guide (opposite page) provides questions to assist learning. Color tabs identify sections particularly relevant to different categories of healthcare providers.

This book is produced by Global-HELP, a not-for-profit organization that produces and distributes free or affordable healthcare education materials worldwide.

It is a great honor to work on this landmark project and to experience the dedication, passion, skill, and sensitivity of Dr. Pirani in originating and managing this project. He combines the abilities of a clinician, surgeon, diplomat, and innovator in achieving the great success of the venture.

I want to give special thanks to Michelle Gutierrez and Deborah Cughan for their professional assistance in producing this book.



Lynn Staheli, MD
Global-HELP Organization
Web site: global-help.org
2008

Note for Readers

Care has been taken to confirm the accuracy of the information presented and to describe generally accepted practices. However, the authors and publisher are not responsible for errors or omissions or for any consequences from application of the information in this book and make no warranty, expressed or implied, with respect to the currency, completeness, or accuracy of the contents of the publication. Application of this information in a particular situation remains the professional responsibility of the practitioner.

Workshop to develop teaching material in Kampala



Study Guide Questions

Answer these questions to test your understanding of what you read.

Pages 10–11: History of Clubfoot Management

Outline early writers' ideas on clubfeet management.
What aspects of clubfoot biology did Dr. Ponseti clarify?

Pages 12–13: Clubfoot Management in Uganda

Outline the history of clubfoot management in Uganda.
Describe the strategy for clubfoot care in Uganda now.
Name key partners in this strategy and their roles.

Pages 14–15: Social and Cultural Barriers

What is the usual reason for a child to be a “no show” for a clubfoot clinic visit?
What are the common social barriers to care?
What are the common cultural barriers to care?
How can healthcare providers help parents overcome barriers?

Pages 16–17: Anatomy, Physiology, and Pathology

Name and describe standard foot and ankle movements.
What causes cavus, adductus, varus, and equinus?
How does the subtalar joint move?
What is its clinical relevance?

Pages 18–19: Information for Parents

What are parents' common questions about clubfeet?
What are parents' common questions about treatment?

Pages 20–21: Screening and Diagnosis

Why is screening for clubfoot important?
What is a visual foot inspection? Who should do it?
How do you make a diagnosis of a clubfoot?
Why assess the whole child?

Pages 22–23: Clubfoot Assessment

What are the different classes of clubfeet?
What does the Pirani Clubfoot Score measure?
What are the Total, Hindfoot, and Midfoot Scores?
How does scoring help in managing a clubfoot?

Pages 24–25: Overview of Management

What are the four steps in the overall management of a child born with clubfeet?
Why is follow-up essential?

Pages 26–27: Clubfoot Clinics

Describe a clinic's patient volumes and staffing arrangements.
What supplies are needed?
How is patient flow organized?
Name other possible roles of a clubfoot clinic.

Pages 28–29: Casting Setup and Technique

What materials should be available before starting?
Describe positioning for the manipulator and assistant.
What are the basic steps for each casting?
What instructions are given to the caregivers before leaving the clinic?

Pages 30–31: Ponseti Corrective Casts

Describe the technique used in manipulating and positioning the foot during cavus correction.
Describe the technique used in cast moulding during cavus correction.
Describe the technique used in manipulating and positioning the foot during adductus and varus correction.
Describe the technique used in cast moulding during adductus and varus correction.

Pages 32–33: Cast Removal

Outline the options technique for removing casts.
Describe possible cast-related complications and management.

Pages 34–35: Tenotomy

What is the indication for tenotomy?
Describe methods used to evaluate calcaneal abduction and ankle dorsiflexion.
How is a tenotomy performed?
Describe the roles performed by the orthopaedic and medical officers during tenotomy.
What signs indicate successful completion of tenotomy?

Pages 36–37: Bracing

What is a SFAB?
Where can SFABs be obtained?

Pages 38–39: Bracing Technique

What purpose does the SFAB serve?
Why is follow-up essential?
When and how should it be fitted?
What helps caregivers use the brace correctly and consistently?

Pages 40–41: Common Management Errors

Describe six common management errors, and when they occur.
Why is it important to identify the head of the talus?
Why is a below-knee cast ineffective?
Why do braces, apart from SFABs, fail to prevent relapse of deformity?

Pages 42–43: Relapse

What causes relapse?
Why is it important to recognize relapse early?
How can relapse be recognized?
What is the treatment of relapse?

Pages 44–45: Anterior Tibialis Tendon Transfer

When is transfer indicated?
What is the standard postoperative care?

Pages 46–47: Difficult Clubfeet

What types of clubfeet can be difficult?
Why is it important to recognize difficult clubfeet?
Describe the complex clubfoot and its management.

6 Contributors

Contributors to this Publication

The efforts of these contributors have made this publication more relevant to Uganda.

Amandua, Jacinto

Commissioner of Clinical Services
Ministry of Health
Project advisor



Amone, Jackson

Assistant Commissioner for Curative Services
Ministry of Health
Member, Management Committee



Beyeza, Tito

Head, Department of Orthopaedics
Makerere University Medical School
Member, Management Committee



Franceschi, Fulvio

Director
Childrens Orthopaedic Rehabilitation Unit
Member, Management Committee



Gita, Sheba

Lecturer, School of Public Health
Makerere University
Project Advisor



Jjumba, Sam

Principal Tutor
School for Orthopaedic officers
Trainer – Ponseti Method



Kayondo, Sam

Acting Principal Tutor
Orthopaedic Technology Training School
Trainer – Bracing



Kaziba, Benon

Tutor
School for Orthopaedic officers
Trainer – Ponseti Method



Kidega, Margaret

Principal
School of Nursing and Midwifery
Kabale



Kisombo, David

Tutor
Orthopaedic Technology Training School
Trainer – Bracing



Kitemagwa, Dirisa

Senior Orthopaedic officer
Mulago Hospital Complex
Senior Trainer – Ponseti Method



Konde-Lule, Joseph

Professor, School of Public Health
Makerere University
Member, Management Committee



Madewo, Geoffrey

Orthopaedic Surgeon
Mulago Hospital Complex
Orthopaedic Coordinator, USCCP



Mainetti, Sergio

Head of Orthopaedic Workshop
Katalemwa Cheshire Home
Senior Trainer – Bracing



Mathias, Richard

Professor, Healthcar Epidemiology
University of British Columbia
Member, Management Committee



Mbonye, Ben

Hon Lecturer, Department of Orthopaedics
Makerere University Medical School
Deputy Project Director, Uganda

**Mugisa, Didus**

Lecturer, Department of Surgery
Makerere University Medical School
Liaison, Department of Surgery

**Musoke, Henry**

Senior Orthopaedic officer
Childrens Orthopaedic Rehabilitation Unit
Senior Trainer – Ponseti Method

**Mutebi, Issac**

Tutor
Orthopaedic Technology Training School
Trainer – Bracing

**Naddumba, Edward**

Senior Consultant, Department of
Orthopaedics
Makerere University Medical School
Project Director, Uganda

**Otim, Alfred**

Dean of Students
Paramedical Training Schools
Trainer – Ponseti Method

**Okello, David**

Orthopaedic Technician
Katalemwa Orthopaedic Workshop
Trainer – Bracing

**Penny, Norgrove**

Coordinator for Orthopaedic Projects
Christian Blind Mission
Member, Management Committee

**Pirani, Shafique**

Professor, Department of Orthopaedics
University of British Columbia
Project Director

**Sewankambo, Nelson**

Dean, Faculty of Medicine
Makerere University

**Staheli, Lynn**

Professor Emeritus, UW, Seattle
Founder, HELP Organization
Editor and Photographer

**Steenbeek, Michiel**

CBM Advisor for Orthopaedic Projects
CORSU
Senior Trainer – Ponseti Method/Bracing

**Steenbeek-Dreise, Marieke**

Project Administrator
USCCP

**Waiswa, Gonzaga**

Orthopaedic Surgeon
Mulago Hospital Complex
Orthopaedic Coordinator, USCCP

**Wanaswa, Nathan**

Tutor
School for Orthopaedic officers
Trainer– Ponseti Method

**Wangobaya, Milton**

Orthopaedic Technologist
Mulago Orthopaedic Workshop
Project Advisor



8 Contributing Organizations

Contributing Organizations


Many organizations have contributed to the Uganda Sustainable Clubfoot Care Project and this publication.

Association of Universities and Colleges of Canada



The Association of Universities and Colleges of Canada is the voice of Canada's universities. It represents 90 Canadian public and private not-for-profit universities and university-degree level colleges. Its mandate is to facilitate the development of public policy on higher education and to encourage cooperation among universities and governments, industry, communities, and institutions in other countries. <http://www.aucc.ca/>

Canadian International Development Agency

The Canadian International Development Agency  (CIDA) is Canada's lead development agency. It has a mandate to reduce poverty and to contribute to a more secure, equitable, and prosperous world. CIDA works in partnership around the world to support sustainable development in developing countries and to offer humanitarian assistance in areas of need. <http://www.acdi-cida.gc.ca>

Childrens Orthopaedic Rehabilitation Unit



CORU seeks to restore ability in children with physical disabilities.

Christian Blind Mission



CBM is an international organization whose primary purpose is to improve the quality of life of the world's poorest people with disabilities. <http://www.cbmi.org>

Global HELP Organization



The Global HELP Organization produces free healthcare publications for developing countries. <http://www.global-help.org>

Makerere University



Makerere University is Uganda's premier institution of higher learning. With a student population of more than 30,000, it ranks as one of the largest in East and Central Africa. <http://www.mak.ac.ug/>

Ministry of Health, Government of Uganda



The Ministry of Health provides health policies, guidance, and standards; facilitates district health services; and manages nationally based health services. It ensures the attainment of a good standard of health by all people in Uganda in order to promote a healthy and productive life. <http://www.health.go.ug/>

Mulago Hospital



Mulago Hospital is an urban, tertiary care facility located in Kampala, Uganda. It is the largest government referral hospital, the main teaching hospital of Makerere University, and the site of the main Clubfoot Clinic of the Uganda Sustainable Clubfoot Care Project. <http://www.mulago.or.ug/>

The Rotary Foundation



The Rotary Foundation is a not-for-profit corporation that supports the efforts of Rotary International to achieve world understanding and peace through international humanitarian, educational, and cultural exchange programs. It is supported solely by voluntary contributions from Rotarians and friends of the Foundation who share its vision of a better world. <http://www.rotary.org/foundation/>

The University of British Columbia



The University of British Columbia aspires to be one of the world's best universities by preparing students to become exceptional global citizens, promoting the values of a civil and sustainable society, and conducting outstanding research to serve the people of British Columbia, Canada, and the world. <http://www.ubc.ca/>

Bibliography

- 1839** Little W.J. A treatise on the nature of club-foot and analagous distortions. London: W. Jeffs, S. Highley.
- 1891** Phelps A.M. The present status of the open incision method for talipes varo-equinus., *New Engl. Med.* 10:217.
- 1893** Farabeuf L.H. *Precis de manual operative.* 4th ed. Masson, Paris.
- 1930** Brockman E.P. Congenital club foot: Its causes, pathology and treatment. John Wright, Bristol
- 1930** Kite J.H. Non-operative treatment of congenital clubfeet. *Southern Med. J.*, 23:337.
- 1950** Steindler A. *Postgraduate lectures on orthopedic diagnosis and indications, Vol. 1.* Springfield, Illinois:Thomas.
- 1961** Huson A. Een, ontleedkundig functioneel Onderzoekvan de Voetwortel. (An anatomical and functional study of the tarsus). Ph.D. dissertation, Leiden University.
- 1963** Ponseti I.V. Smoley E.N. Congenital Clubfoot: The Results of Treatment. *J Bone Joint Surg.* 45A:2261.
- 1966** Ponseti I.V. Becker J.R. Congenital Metatarsus Adductus: The Results of Treatment. *J Bone Joint Surg.* 43A:702.
- 1972** Campos J. Ponseti I.V. Observations on Pathogenesis and Treatment of Congenital Clubfoot. *Clin Orth and Rel Res.* 84:50
- 1974** Ionasescu V. Maynard J.A. Ponseti I.V. Zellweger H. The Role of Collagen in the Pathogenesis of Idiopathic Clubfoot: Biochemical and Electron Microscopic Correlations. *Helvetica Paediatrica Acta* 29:305.
- 1980** Ippolito E. Ponseti I.V. Congenital Clubfoot in the Human Fetus: A Histological Study. *J Bone Joint Surg* 62A:8.
- 1980** Laaveg S.J. Ponseti I.V. Long-term Results of Treatment of Congenital Clubfoot. *J Bone Joint Surg* 62A:23
- 1981** Brand R.A. Laaveg S.J. Crowninshield R.D. Ponseti I.V. The Center of Pressure Path in Treated Clubfoot. *Clin Orth and Rel Res*,160:43.
- 1981** Ponseti I.V. El-Khoury G.Y. Ippolito E. Weinstein S.L. A Radiographic Study of Skeletal Deformities in Treated Clubfoot. *Clin Orth and Rel Res* 160:30.
- 1992** Ponseti I.V. Treatment of Congenital Clubfoot. *J Bone Joint Surg* 74A:448.
- 1994** Ponseti I.V. The Treatment of Congenital Clubfoot *Journal of Orthopaedic and Sports Physical Therapy* 20:1.
- 1994** Farsetti P. Weinstein S.L. Ponseti I.V. The Long-term Functional and Radiographic Outcomes of Untreated and Non-Operatively Treated Metatarsus Adductus. *J Bone Joint Surg* 76A:257.
- 1995** Cooper D.M. Dietz F.R. Treatment of Idiopathic Clubfoot: A Thirty-Year Follow-up Note *J Bone Joint Surg* 77A:1477
- 1996** Ponseti I.V. *Congenital Clubfoot: Fundamentals of Treatment.* Oxford University Press.
- 1997** Ponseti I.V. Common Errors in the Treatment of Congenital Clubfoot. *Int Orthopaedics* 21:137.
- 1998** Ponseti I.V. Correction of the Talar Neck Angle in Congenital Clubfoot with Sequential Manipulation and Casting. *Iowa Orthopaedic J* 18:74
- 2000** Ponseti I.V. Clubfoot Management. *J Pediatr Orthop* 20:699.
- 2001** Pirani S. Zeznik L. Hodges D. Magnetic Resonance Imaging Study of the Congenital Clubfoot Treated with the Ponseti Method. *J Pediatr Orthop* 21:719
- 2002** Herzenberg J. Ponseti Versus Traditional Methods of Casting for Idiopathic Clubfoot. *J Pediatr Orthop* 22:517.
- 2003** Ippolito E. Farsetti P. Caterini R. Tudisco C. Long-term Comparative Results in Patients with Congenital Clubfoot Treated with Two Different Protocols. *J Bone Joint Surg* 85A:1286.
- 2003** Morcuende J. Egbert M. Ponseti I.V. The Effect of the Internet in the Treatment of Congenital Idiopathic Clubfoot. *Iowa Orthop J* 23:83.
- 2003** Macharia J. The Idiopathic Clubfoot: Short-term Results of Treatment with the Ponseti Method at Mulago Hospital. Masters Dissertation. Makerere University.
- 2004** Dobbs M. Treatment of Idiopathic Clubfeet: Factors Predictive of Outcome *J. Bone Joint Surg. Am.* 86:22
- 2004** Morcuende J. Dolan L. Dietz F. Ponseti I.V. Radical Reduction in the Rate of Extensive Corrective Surgery for Clubfoot Using the Ponseti Method. *Pediatrics* 113:376
- 2005** Morcuende J. Results of an Accelerated Ponseti for Clubfoot. *J Pediatr Orthop* 25:623
- 2005** Tindall A. Results of Manipulation of Idiopathic Clubfoot Deformity in Malawi by Orthopaedic Clinical Officers Using the Ponseti Method: A Realistic Alternative for the Developing World? *J Pediatr Orthop* 25:627
- 2005** Konde-Lule J. Gitta S. McElroy T and the Uganda Sustainable Clubfoot Care Project. Understanding Clubfoot in Uganda: A Rapid Ethnographic Study. Makerere University
- 2006** Dobbs M.B. Long-Term Follow-up of Patients with Clubfeet Treated with Extensive Soft-Tissue Release. *J. Bone Joint Surg. Am.* 88:986
- 2006** Ponseti I.V. Treatment of the Complex Idiopathic Clubfoot, *Clin Orth Rel Res* 451:171.
- 2006** Shack N. Early results of a physiotherapist-delivered Ponseti service for the management of idiopathic congenital talipes equinovarus foot deformity; *J. Bone Joint Surg* 88-B: 1085
- 2007** McElroy T. Konde-Lule J. Gitta S and the Uganda Sustainable Clubfoot Care Project. Understanding the Barriers to Clubfoot Treatment Adherence in Uganda: A Rapid Ethnographic Study. *Disability and Rehabilitation* 29:845
- 2008** Ponseti, I.V. *Congenital Clubfeet: Fundamentals of Treatment, 2nd Edition.* Department of Orthopaedics, University of Iowa, Iowa City, IA, 52242

10 History of Clubfoot Management

History of Clubfoot Management

Humankind has known of clubfeet since time immemorial. Treatment modalities were always controversial, varying according to the capabilities of the era. Remarkably, over the last 10 years, almost all clubfoot experts have migrated to using the Ponseti Method.

Early

Egyptian tomb paintings show Pharaoh Siptah of the 19th Dynasty to have clubfeet.

Hippocrates was the first to write on clubfeet. He recognized that treatment should start early, before bony deformity is established.

Modern medicine (18th century onwards)

The first casts (egg-white-soaked bandages) were applied by William Cheselden at St. Thomas's Hospital, London. The first achilles tenotomies were by Delpech, Stomeyer, and Little in the 1820s. Plaster of paris casts were first used by M. Guerin (1833). William Adams described pathology after dissecting stillborns.

Surgical methods The advent of antisepsis, anaesthesia and the surgical tourniquet allowed a surgical approach. Extensive postero-medial releases were developed by Phelps, Duval, Ogston, and others (1870 and later). Steindler (1950) recognized poor results in more than 50% of surgical cases, leading to a reappraisal of nonsurgical methods.

Hiram Kite was a leading advocate of nonsurgical management (1930). He advised a sequential correction of the clubfoot deformity. His technique, however, failed to take advantage of the synchronous movements of the tarsal bones making up the subtalar joint. He reported a prolonged period of treatment (average 22 months) that was necessary to correct the deformity.

Clubfeet and the Ponseti Method

Ponseti – a keen clinician and careful scientist

Ponseti recognized that surgical approaches to clubfeet fail – surgery results in stiff and painful feet. He sought to develop a more effective nonsurgical solution by returning to basic biology. He advised simultaneous correction of cavus, adductus, and varus followed by correction of equinus [A]. Ponseti's technique of correction took advantage of the synchronous movements of the tarsal bones making up the subtalar joint to unlock the deformity. He found that correction of the deformity could be achieved in just 5 weeks.

Biology clarified by Ponseti

Abnormal clubfeet anatomy Campos and Ponseti's dissections of stillborns with clubfeet (1966) revealed tarsal shape abnormalities, abnormal intertarsal relationships, and abnormalities of the tendons and ligaments posteriorly and medially. In particular, the navicular [B, outlined in red] is medially displaced on the talus [B, outlined in yellow].

Deformity assessment In infancy, most tarsal bones are minimally ossified. Ponseti understood that radiographs would therefore be unhelpful in most cases. He emphasized clinical methods of assessment of deformity in decision making.

Kinematic coupling Ponseti clarified tarsal bone movements in normal and clubfeet by cineradiographic studies and understood its importance. Kinematic coupling is a term given by Farabeuf (1893) and Huson (1961) to tarsal bone movement motion coupling.

Calcaneal adduction is accompanied by inversion and flexion of the calcaneus.

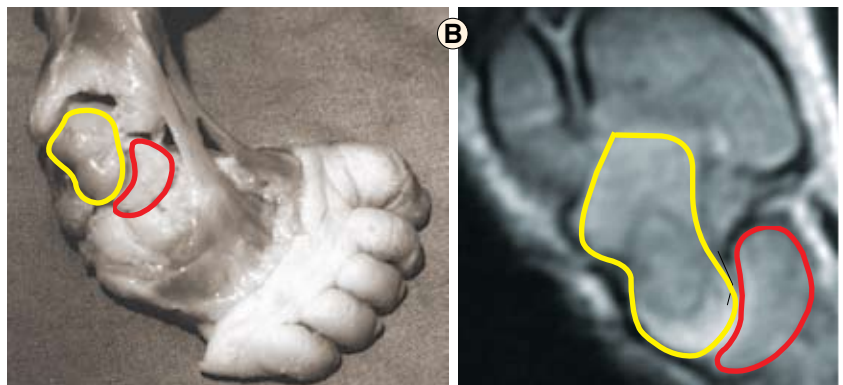
Calcaneal abduction is accompanied by eversion and extension. In other words, calcaneal inversion or varus will correct only if it is abducted.

Response to low load Ponseti postulated that young, fast-

A

"A well conducted orthopedic treatment, based on a sound understanding of the functional anatomy of the foot, and on the biological response of young connective tissue and bone to changes in direction of mechanical stimuli, can gradually reduce or almost eliminate these deformities in most clubfeet."

(Ponseti 1996)



growing connective tissues (tendons and ligaments) and cartilage would show a biologic response to low load tensions exerted by his manipulation and casting technique – that contractures would stretch and tarsal cartilage abnormalities would remodel [previous page, B].

Pirani’s MRI studies (2001) confirmed this biologic response. The MRIs showed that as the foot corrected clinically [A to B], individual tarsal abnormalities such as a medially inclined talar neck (in yellow) and intertarsal relationships such as a medially displaced navicular (in red) corrected [D and E].

Clinical application

Early disinterest Ponseti developed his technique of manipulation and casting. He performed a clinical trial of his technique on his patients and reported on his findings on several occasions (1963, 1972, 1980, 1992). However, doctors treating clubfeet were initially slow to change their patterns of practice and adopt the Ponseti Method. The pathology and biology remained poorly understood. Ponseti’s reports were not given due credit, possibly because they were not read accurately.

Delayed acceptance Several factors led to the widespread adoption of Ponseti’s technique at the turn of the 21st century.

Very satisfactory long-term outcomes were reported by independent observers (Cooper and Deitz 1995) [C].

MRI studies were performed and reported (Pirani 2001).

Internet-driven parent demand of nonsurgical option ensued (Morcuende and Egbert 2003).

Re-emphasis on technical aspects was presented by Ponseti’s monograph on clubfeet (*Congenital Clubfoot–Fundamentals of Treatment* 1996).

Clarification of Common Errors were addressed (Ponseti 1997).

Clinical experience of other investigators documenting effectiveness of the method prompted a reconsideration of the need for surgical release (Herzenberg 2002).

Developments and refinements

Several other investigators have contributed to modern thinking about clubfoot.

Bracing is necessary to prevent relapse (Morcuende 2004).

Long-term outcomes from surgery are poor [C] (Dobbs 2006).

The technique is effective in paramedical hands as shown in Uganda (Macharia/Pirani 2003), Malawi (Tindall 2005) and United Kingdom (Shack 2006).

The technique is effective in older children The upper age limit remains to be established (Nogueira 2006).

The complex clubfoot variant needs early identification, as it needs a modification in management. Results remain rewarding (Ponseti 2006).

Syndromic clubfeet respond to the method. Most correct; however, more casts usually are needed and relapse is more common.

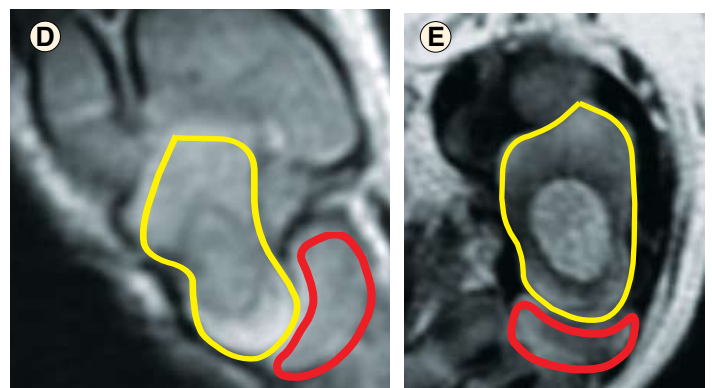
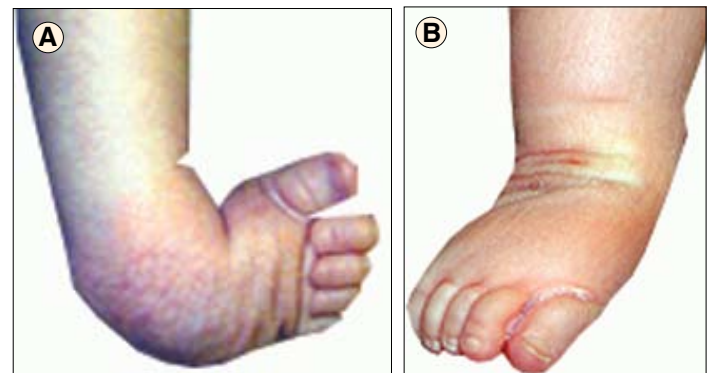
An accelerated protocol of management with cast changes every 4 to 5 days is equally effective and can shorten the time needed to obtain correction (Morcuende 2005).

©

Long-Term Outcomes of Clubfoot Treatment – Adapted from Treatment of Idiopathic Clubfoot: A Thirty Year Follow-up Note, (JBJS 77A, 1477) and Long-Term Follow-up of Patients with Clubfeet Treated with Extensive Soft Tissue Release (JBJS 88A,986)

	Surgical Treatment	Ponseti Treatment
Good and Excellent	33%	78%
Fair and Poor	67%	22%

“Operative patients had less physical function, more bodily pain, less general health, and less social function than Ponseti-treated patients.” (Dobbs 2006)



12 Clubfoot Management in Uganda

Clubfoot Management in Uganda

Before Ponseti management, clubfoot management in Uganda mirrored management elsewhere in developing nations with scarce surgical resources.

Clubfoot – A surgical diagnosis

Surgery was considered necessary in most cases to correct the deformity.

Detection at birth The importance of this was not emphasized, as casting was considered ineffective and surgery largely unavailable.

Management Where available, treatment was with the Kite method by paramedical staff (orthopaedic officers) with biweekly below-knee plaster of paris casts. Only 10% of deformities corrected after 6 months of casting.

Outcome Most caregivers abandoned treatment, exhausted by repeated clinic visits with little or no improvement. Most children grew up burdened by their neglected clubfeet.

Consequences

Atria estimated there were 10,000 children with neglected clubfeet in Uganda in 1994. Neglected clubfeet have several negative consequences.

On the Individual In an agrarian society, pain with walking results in disability, decreased opportunity for gainful employment, and social marginalization. Females are particularly vulnerable – mothers carry the burden of care for children, and afflicted girls are less likely to marry. Each affected individual faces a downward spiral of deformity, disability, dependency, demoralization, despair, and depression.

On the family The family carries the burden of providing for the disabled and are financially poorer.

On society Ill health is the leading cause and consequence of poverty in developing nations.

Ponseti Method Introduction to Uganda

In 1999, with evidence that the Ponseti Method was effective in correcting deformity in clubfeet, stakeholders reached consensus to introduce the Ponseti Method to Uganda as a potential solution to preventing the consequences of neglected clubfeet.

Early experience

A trial of the Ponseti Method was conducted at the Mulago Hospital Clubfoot Clinic on infants presenting with congenital clubfeet. The model of care advocated:

Manipulation and casting by orthopaedic officers under the supervision of a medical officer.

Tenotomy by a medical officer.

Steenbeek foot abduction bracing to prevent relapse of deformity.

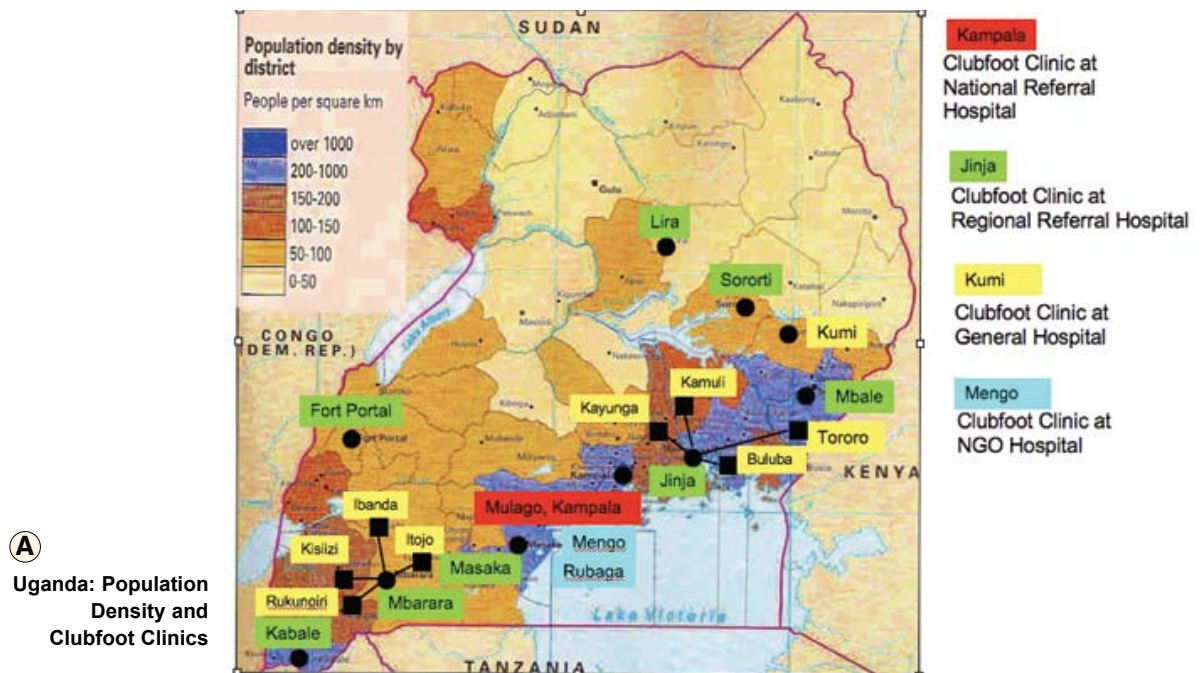
Results Macharia (2003) confirmed clubfeet in Uganda could be successfully corrected by orthopaedic officers.

Barriers

Macharia's work suggested that barriers prevented successful outcomes in all.

Barriers for caregivers Many children present late, or not at all, for treatment for many reasons, including lack of awareness of the deformity or concerns about cost of care.

Barriers for healthcare providers Inconsistency of supplies at many clinics and variable quality of support and supervision of orthopaedic officers reduced the effectiveness of the treatment method.



A Sustainable Clubfoot Care Program

Healthcare initiatives that are economically and socially feasible for society are more likely to be sustainable. The Uganda Project is expanding on early experience in Uganda with the Ponseti Method by building capacity throughout Uganda for sustainable care of the child born with a clubfoot. Multiple partners, each playing an important role, have collaborated to develop a common national strategy. A concerted effort is needed to reduce barriers for patients and healthcare providers.

Uganda's strategy to manage clubfeet

Screening, diagnosis, and treatment Healthcare workers attending births should screen for foot deformities at the examination of the newborn. Babies with suspected foot deformity are to be referred early to one of a network of clubfoot clinics across the country. Trained orthopaedic officers will confirm the diagnosis and treat with the Ponseti Method.

Training in clubfoot screening, diagnosis, and treatment is to become routine for healthcare professionals that regularly come into contact with infants and children.

Policy and advocacy consist of standardized careplans for clubfeet and advocacy for resources for care of children with clubfeet.

Partners and roles

The Ministry of Health The Commissioner of Clinical Services coordinates clubfoot activities of the Ministry.

Policy is created to guide the care of children born with clubfeet. All children born in Uganda with clubfeet should be managed by the Ponseti Method.

Standards for screening, treatment, and support/supervision are created and monitored.

Create awareness in Ugandan society and healthcare workers for the need to detect clubfeet at birth and start early treatment.

Resource allocation Incidence and census data allow the Ministry to estimate births of children with clubfeet by district and to allocate resources. The materials necessary for treatment are on a credit line with the National Medical Stores.

Uganda's healthcare schools All medical, nursing and midwifery, and paramedical schools (for orthopaedic officers and technologists) will include in their curricula, as appropriate, screening for foot deformities at birth, congenital clubfoot diagnosis, and its management by the Ponseti Method.

New modules The Project has produced new modules for clubfoot detection and treatment for all cadres of healthcare students.

This teaching manual provides specific teaching materials for each core group of healthcare students.

Uganda's healthcare institutions Only 35% of births in Uganda occur under the supervision of trained healthcare

workers such as midwives. Inform all healthcare providers seeing babies and children of the opportunities for screening for foot deformities during early life by a visual foot inspection and to refer if positive. A failure to detect a foot deformity will deprive the child of the opportunity to have it corrected.

Midwives and nurses The examination of the newborn is the best time to perform a visual foot inspection.

Immunization workers In many areas immunization rates exceed 90% and continue at regular intervals. A visual foot inspection should be performed at every immunization. These visits provide an excellent opportunity for trained immunization workers to screen for foot deformities in children born in the village.

The "Child Health Card" will have a reminder to screen for foot deformities.

Referral Midwives, nurses, immunization workers and others suspecting a foot abnormality on visual foot inspection are to refer the infant to the nearest clubfoot clinic.

A network of clubfoot clinics staffed by trained orthopaedic officers and doctors continues to grow at many regional and general hospitals across the country [previous page, A].

Orthopaedic officers are specially trained in the Ponseti Method. They are most suited to making the diagnosis of a clubfoot and treating it.

Tenotomies are performed by a surgeon or medical officer.

Steenbeek foot abduction braces are made by orthopaedic technicians and technologists at government and NGO orthopaedic workshops.

School of Public Health The school's role is to research issues surrounding this initiative (e.g., an incidence survey of clubfeet at birth in Uganda, an ethnocultural survey of clubfeet in Uganda) and advising on public health aspects.

Makerere University and University of British Columbia The updated curriculum content and teaching materials for clubfoot detection and treatment by the Ponseti Method are a collaborative effort of the University of British Columbia, Makerere University Medical School, and other Ugandan Schools of Healthcare.

Christian Blind Mission Through CORU, the role of the Christian Blind Mission includes providing expertise and facilities for the activities of the project.

14 Social and Cultural Barriers

Social and Cultural Barriers

To understand what Ugandans know, feel, and believe about clubfoot, the Project commissioned an ethnocultural survey of clubfoot in Uganda. This highlighted the issues of barriers to care as an important problem. Contact the Department of Orthopaedics at Makerere for a copy of the survey for complete details.

Most parents want their children to be healthy. A “no show” child at the clinic usually means that the parent or caregiver met a barrier to attending the clinic they were unable to overcome. The child therefore suffers. If healthcare workers understand these barriers, they can work with caregivers to develop strategies to overcome them [B].

A Observations about Barriers by Dean Nathan Wanaswa

1. Some parents believe clubfoot is a curse by a relative or a supernatural power and often blame their ancestors.
2. If a clubfoot runs in the family, the father may decline treatment as the deformity identifies the family line.
3. The mother of the child may be divorced because the father cannot accept that he is the father and considers his wife was unfaithful.
4. Untreated, a girl with clubfoot may become pregnant without marriage; if she has a child with a clubfoot, the father is angry as the child is a disgrace to the family. The girl cannot marry as she is considered cursed. Mother will not bring the child for treatment.
5. Some believe that the condition will resolve with time. It does not. There can be considerable delay before treatment is sought.
6. Some fear a plaster cast. They believe it acquires lice.
7. Many believe the deformity cannot be corrected.
8. Most fear the hospital. Doctors and nurses abuse and harass them. They fear surgery, and are concerned that the doctor may cut off the child's foot. They fear seeing strange diseases and deformities.
9. Many feel small and just do not want to be with better educated people because they feel inferior. They are embarrassed to show their child in public. The poor cannot afford clothing that they feel necessary to appear in public so they stay home. Husbands consider the wife the cause of the problem and refuse to bring the child to the hospital.
10. Long distances to hospitals and expensive transport makes management difficult.
11. Sickness, either in the child or some other family member (AIDS), may interfere with treatment.
12. Relatives may not be supportive. They may disown the child, feeling that it is from another family line and suggest that the child is cursed.

Barriers – Social

Poverty

Uganda continues to make economic progress. Yet one-third still live below the poverty line (DFID 2007). Despite parents' wishes to have their child treated, they may not be able to cope financially and drop out. In one survey, 60% of caregivers said they had difficulty meeting the costs, having to borrow or sacrifice other basic needs. Even though care at Uganda's hospitals is free of charge, constraints in supplies can mean that caregivers have to buy materials. This burden is aggravated if careproviders also charge.

Conflict with other maternal responsibilities

Most Ugandans live in rural areas and are subsistence farmers. The average household is seven people. Traditionally, females are responsible for household tasks such as cooking and child-care. The mother may become overwhelmed and feel unable to take on the additional burden of the child's treatment. She may start treatment but drop out due to the difficulties.

Travel to clinic

Simply getting to the clinic is usually a long and costly effort. Once at the clinic, the parent and child may face long lines [A].

Challenges of treatment process

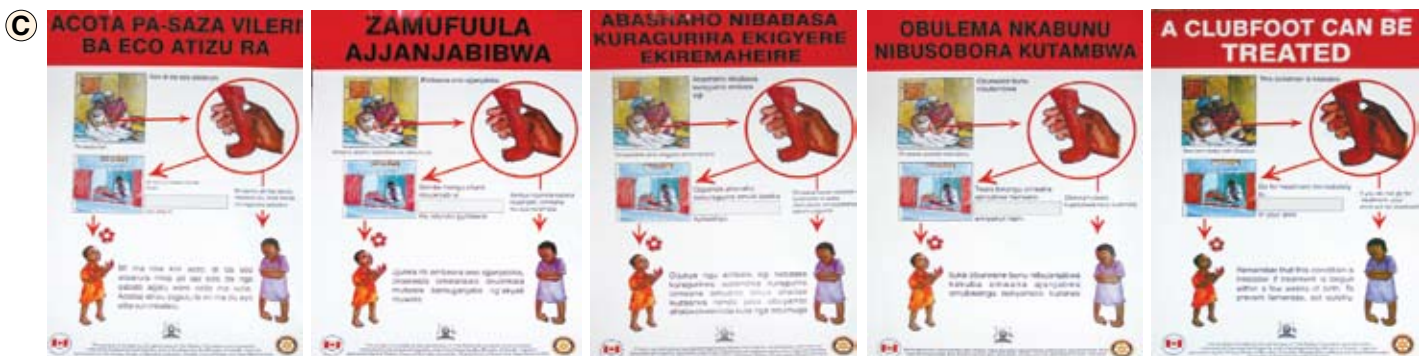Parents worry about whether their child will have pain, or how to bathe and carry the child. They may feel shame. The prospect of endless visits to the clinic can be daunting [A].

Lack of paternal involvement and support

Whereas the father is usually the breadwinner (and therefore controller of family finances), the mother is the primary caregiver for children. Mothers need the fathers' understanding and financial support to follow the treatment protocol. However, only one out of ten children at the clinic come with their fathers. Fathers do not always have the opportunity to completely understand that the clubfoot is a completely correctable condition, provided treatment is followed.

B

“When we fail to recognize these macro level issues, we are at risk of blaming parents and their families for non-compliance.”
(USCCP Ethnocultural Survey)



Barriers – Cultural

Many healthcare approaches

People all over the world use both modern and alternative medicines. Uganda is no exception. Parents often seek care from traditional healthcare practitioners, as they are easily available in their communities. However, these treatments are ineffective for clubfoot, and delay the parent from seeking effective care from the medical system [A]. Delayed presentation complicates management and can compromise outcomes, especially if the child has already started walking.

Beliefs

In some Ugandan communities there are beliefs that clubfoot is caused by evil spirits, witchcraft, a curse, or the mother's misdeeds, and that treatments are ineffective. This results in a delay in seeking care with consequences as indicated above [previous page, A].

Stigma

Often a child with a disability is a source of shame and is hidden by the family [previous page, A].

Village birth

Infants born in the village pose a special problem. They will not normally have the benefit of an examination of the newborn by a trained healthcare worker. The families may have no awareness of the diagnosis or management options.

A

"You talk to the parents and advise them it can be fixed. It is important to listen to the parents' beliefs and then to discuss your beliefs. You can then reach a compromise that will allow the parents to adhere to treatment. If you respect them and their beliefs, they will come back." (Practitioner treating clubfoot, Uganda)

B



Barriers – How to Help

Help parents overcome barriers by the following measures.

Establish clubfoot clinics

A network of clubfoot clinics across Uganda encourages the same standards of free, quality, and effective care. You can help by establishing a clinic and advocating for clinic space, materials, and personnel with your healthcare administrators.

Involve fathers

Encourage fathers to attend the clubfoot clinic with the mothers and to become involved in treatment. Fathers who feel involved and understand are more likely to support the mothers in following treatment for the child [B].

Discuss management and plan follow-up

Inform caregivers of the entire treatment plan (20 visits over 4 years). Discussing and planning the entire treatment at the start encourages families to plan how to gather necessary funds. Inform parents that the cost of care will be covered by the hospital.

Partnerships

Encourage "care-sharing" partnerships to manage barriers. Parents and other caregivers share the financial burden and other family responsibilities. Healthcare workers (orthopaedic officers, orthopaedic technicians, nurses and doctors) share health delivery responsibilities. Consider asking local churches, mosques, service clubs, and NGOs to assist the very poor by facilitating transport or offering other services.

Education, respect, reassurance

Educate parents and the community [C] by informing about clubfeet, its causes, and that the medical system can manage these problems. This will help make the condition more acceptable. Educate those in birthing and immunization clinics to screen for foot deformities with a visual foot inspection and refer if positive. Posters help [opposite page, C].

Respect mothers' needs to return quickly to their other duties at home by avoiding excessive waiting in clinics.

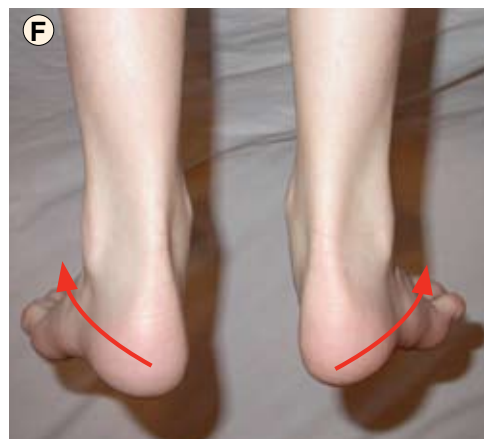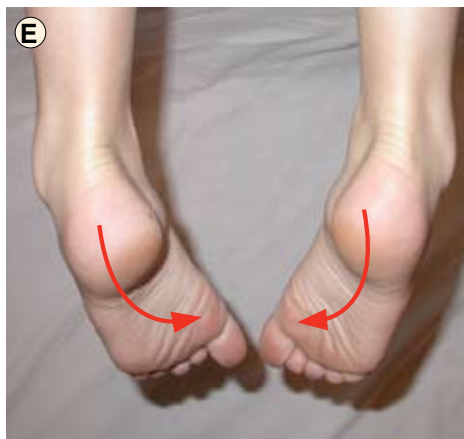
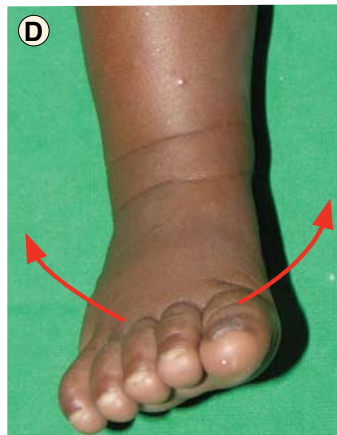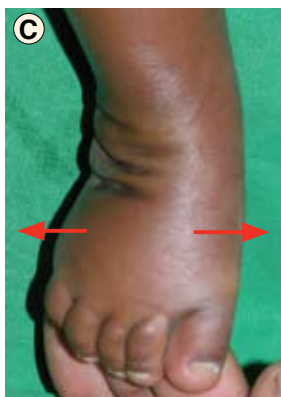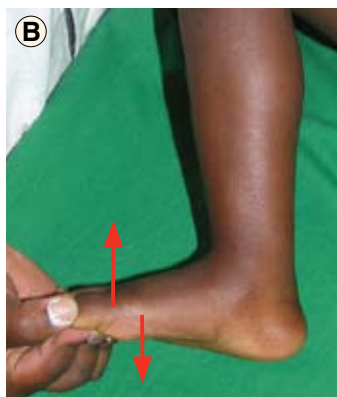
Reassure that the cause is not the parents' fault and treatment is highly effective but takes time.

C

Education For Parents of Children with Clubfeet

Inform parents about clubfeet and the appropriate management. This information explains the cause of the problem and averts common misconceptions. Include a description of the appearance of the clubfoot, the importance of early treatment, and reassurance that treatment can fully correct the deformity. Emphasize that clubfeet can occur in any family and is not caused by any behaviors of the parents or curse. It is simply a medical condition that can be corrected.

Ankle and Foot Movements	
Ankle Extension	Foot moves in a dorsal direction [B]
Ankle Flexion	Foot moves in a plantar direction [B]
Foot Adduction	Distal part of foot moves towards median body plane [C]
Foot Abduction	Distal part of foot moves away from median body plane [C]
Foot Inversion	Plantar aspect of foot moves towards median body plane [D]
Foot Eversion	Plantar aspect of foot moves away from median body plane [D]
Foot Supination	Combined Inversion, adduction and flexion of foot [E]
Foot Pronation	Combined eversion, abduction, and extension of foot [F]



Anatomy, Physiology, and Pathology

The bones of the newborn's foot are largely formed in cartilage, which is less rigid and more easily moulded by external forces than bone. With growth, the cartilage is gradually replaced by bone except for joint surfaces.

Movements

The joints of the foot move in many directions. Terminology can be confusing. Its useful to consider a standard nomenclature for ankle and foot movements [A].

Joints

Ankle joint This lies between the tibia, fibula and talus. Ankle movements [B] are dorsiflexion and plantarflexion.

Subtalar and midtarsal joints The subtalar joint lies between the talus and calcaneus. The midtarsal joints include the talonavicular and calcaneocuboid joints. Subtalar, ankle and midtarsal joints move together and result in foot supination [E] and pronation [F].

Muscles

Muscles provide the power to make the foot joints move:

Gastrosoleus flexes the ankle.

Tibialis anterior extends the ankle and supinates the foot.

Tibialis posterior flexes the ankle and supinates the foot.

Long toe flexors flex the ankle and toes.

Long toe extensors extend the ankle and toes.

Peroneals flex the ankle and pronate the foot.

Ligaments

Stability of the foot is provided by ligaments. Ligaments are strong fibrous bands that connect bones and allow limited motion.

Clubfoot Pathology

Muscles of the foot and leg are smaller than normal – especially the gastrocnemius. The more severe the deformity, the greater the discrepancy. Medial and posterior ligaments are thick and taut and hold the foot in a deformed position. They prevent the foot from passively being put through a full range of motion.

Congenital clubfoot is a complex deformity with four components: cavus, adductus, varus, and equinus.

Cavus

The foot's medial longitudinal arch is increased by plantarflexion of the first ray [page 21, B].

Adductus

The distal foot is deviated towards the median body plane.

Talo-navicular joint The navicular is severely medially displaced [A and B]. It articulates only with the medial part of the talar head. The lateral part of the talar head remains uncovered. The medial pole of the navicular approaches the medial malleolus. The talar neck is deviated medially and plantarward.

Calcaneo-cuboid joint The cuboid is medially displaced and adducted in front of the calcaneus [A and B]. Only the medial part of the anterior tuberosity of the calcaneus articulates with the cuboid. The calcaneocuboid joint is oblique in orientation instead of transverse.

Varus

The hindfoot is deviated towards the midline. This is best appreciated by looking at the heel from behind [page 21, C].

The calcaneus is adducted and inverted under the talus. The anterior tuberosity of the calcaneus lies under the head of the talus rather than lateral to it [A and B].

Equinus

The foot points down [page 21, E].

The ankle joint is severely plantarflexed [A and B].

The subtalar joint is flexed as part of foot supination.

Functional Anatomy

It is important to understand the movements of the subtalar joint. This helps explain the nature of the clubfoot deformity and the foot movements necessary in the Ponseti Method of correcting deformity.

Movements of the subtalar joint

Joint movements are determined by the curvatures of the joint surfaces and their restraining ligaments. Movements of the subtalar joint are complex; however, the following interdependencies are useful to remember.

In foot supination, the calcaneus adducts, inverts, and plantar flexes under the talus [previous page, E].

In foot pronation the calcaneus abducts, everts, and dorsiflexes under the talus [previous page, F].

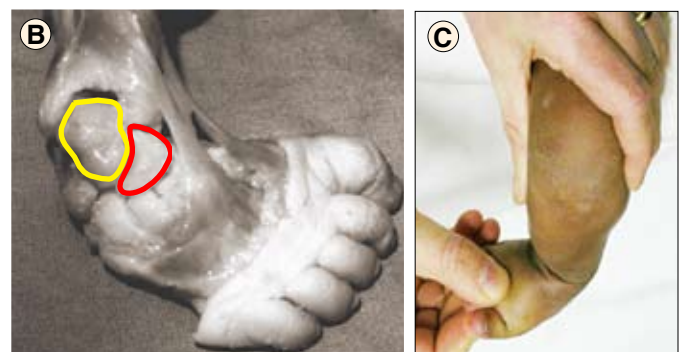
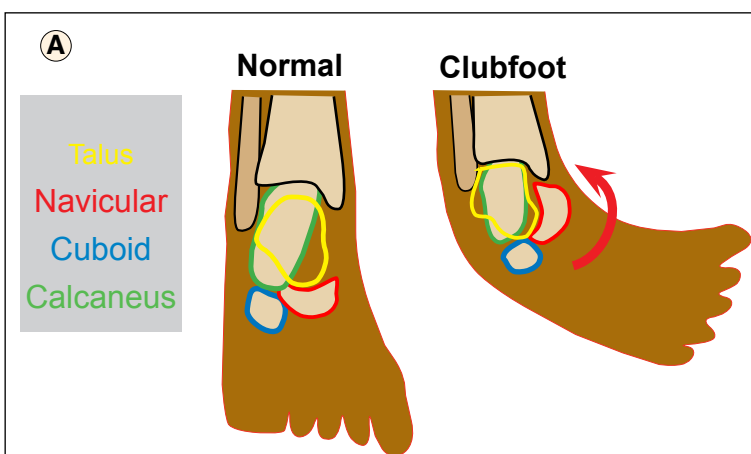
Nature of the deformity

In a clubfoot, consider the tarsal bones to be in the most extreme position caused by excessive pull of the gastrosoleus, tibialis anterior and tibialis posterior [A and B] – giving rise to the adducted, flexed and supinated position of the calcaneus under the talus.

Clinical relevance

This calcaneal malposition needs to be corrected. To do so, abduct the forefoot with counterpressure against the head of the talus. This causes the calcaneus to abduct. Subtalar motion interdependencies ensure that as the calcaneus abducts, it simultaneously everts and dorsiflexes. The clinical deformities of midfoot adduction, heel varus and equinus arising from calcaneal plantarflexion are therefore corrected together.

It is very important not to touch the heel or block the cuboid from abducting because this blocks normal subtalar motion. Remember that the normal infant's foot abducts 70–80 degrees [C]. Calcaneal dorsiflexion occurs mainly during terminal abduction. Therefore, a clubfoot is not adequately corrected until full abduction is obtained. Abducting the foot only to neutral position is not adequate. Calcaneal varus and extension do not correct fully, and relapse is inevitable.



Information for Parents

Take a few moments to answer the questions of parents and caregivers. Informed parents are more likely to cope with the demands placed on them by the treatment protocol [A]. Here are some standard questions and answers.

Are there different types of clubfeet?

Yes. There are three kinds. A few (positional clubfeet) are due to a lack of room in the womb for the baby, for example if the baby is large or if there are twins. The foot is pushed or squeezed on one side. These clubfeet get better quite quickly after birth. With the most common type (congenital idiopathic clubfeet), only the feet are affected, whereas with the third type (syndromic clubfeet), other parts of the body may also be affected.

What causes clubfeet?

Science is trying to find the exact cause. Most experts feel that clubfeet are caused by a combination of genetic predisposition and as yet unidentified environmental factors. Clubfeet are not anyone's fault. They are not due to witchcraft or curses.

Do clubfeet run in families?

In the community at large, the rate of clubfeet is about one baby in a thousand. However, if clubfoot is already in the family, there is a higher rate. For example, if a parent has a clubfoot, there is a 3% to 4% chance that the offspring will also be affected [B, white arrows]. If both parents have clubfeet, the offspring have a 30% chance of developing clubfoot.

Are Ugandans more affected than others?

Surveys have shown that the incidence of clubfeet in Uganda is 1.2 affected babies per one thousand live births. This is the same as most other places in the world.

About Treatment

What is the best treatment for clubfeet?

Most experts everywhere now agree that the best treatment for clubfeet regardless of cost is the Ponseti Method. The outcomes are most gratifying for both the patient and the healthcare provider.

What is the Ponseti Method?

At birth, the child's foot is soft and supple like a green shoot of a young plant. Just as you can bend a green shoot without hurting it, you can straighten a clubfoot in an infant without hurting the foot or the infant. The Ponseti Method is a way of straightening a clubfoot by gently pushing the foot towards the correct position and then applying a holding cast. The time in cast loosens the foot a little more, so that at the next visit, it can be further corrected. Correction is completed by a small cut just above the heel before the final cast. To prevent the clubfoot from coming back, a brace is worn until 4 years of age.

When should the treatment start?

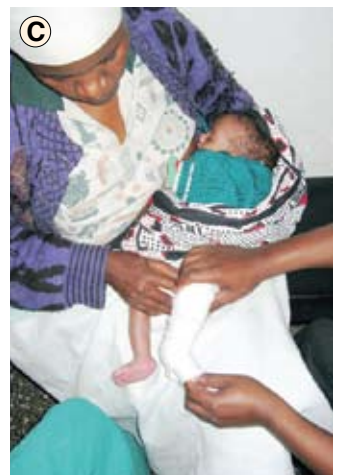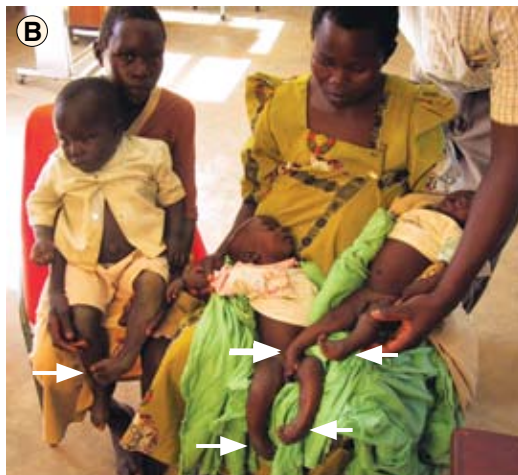
The foot is most receptive to treatment at or within a few weeks after birth [C]. Treatment is still effective if started later, but it can be more complicated and take longer. Start treatment as early as family circumstances permit enough visits for the treatment to be fully effective.

When treatment is started early, how many cast changes are usually required?

Most clubfeet are corrected in approximately five to seven casts. Usually they are changed either weekly or twice a week. If the deformity is not corrected after eight or nine casts, the treatment may be faulty.

How late can treatment be started and still be helpful?

Treatment is less effective if started after the child starts to walk. After walking age, treatment still helps, but there is a higher chance that up to 12 casts or perhaps surgery may be necessary to achieve full correction.



Is surgery needed?

In the past, most doctors believed extensive surgery under a general anaesthetic was necessary for correction. This is no longer the case. Most cases now need only a small cut just above the heel before the final cast. This is done in the clinic under local anaesthetic. Extensive surgery for most patients is not necessary nowadays.

How often does Ponseti Management fail?

Correctly applied, the method is successful in correcting the deformity in the vast majority of cases [A]. The success rate depends on the experience of the treating team, the reliability of the family, and the degree of stiffness of the foot. Some clubfeet (called syndromic clubfeet), such as those seen with arthrogryposis or myelomeningocele, can be more stiff and difficult to correct. However, the most common causes of failure are either difficulty in the child getting to the clinic for all visits during the casting phase, or difficulties with the child wearing the brace until 4 years of age.

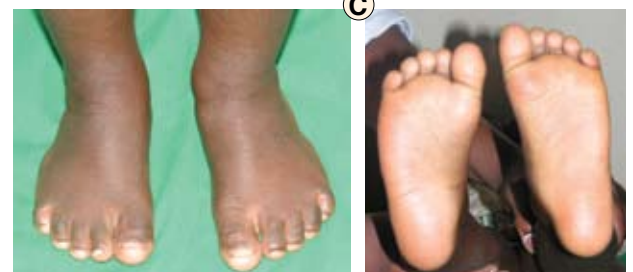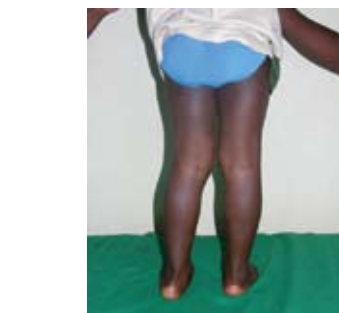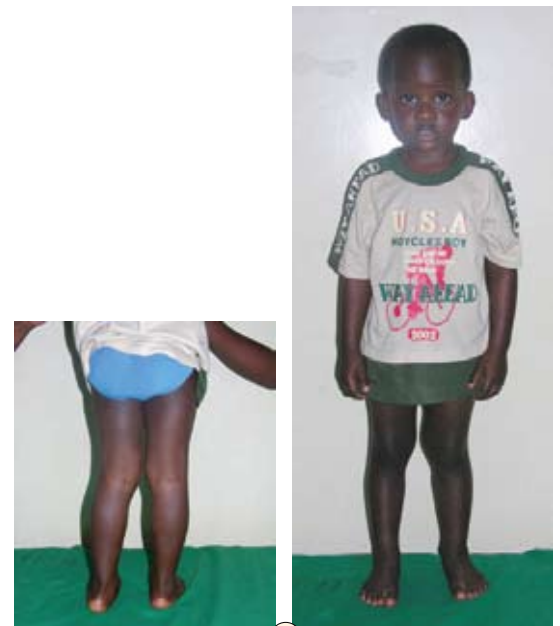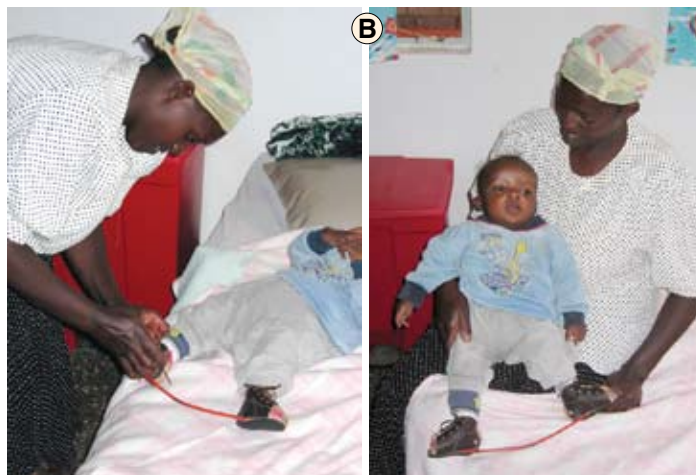
I am worried I will not be able to cope with bracing my child – what will help me cope?

Remember that all parents at sometime feel as if they will not be able to cope with the problems their children bring. And yet almost all parents, after some consideration and planning, manage. It helps to remind the parent of a few things. First, a properly fitting brace should not be painful for the child [B]. If the child cries, they should check for sore areas and have the brace adjusted to fit properly. Second, make putting the brace on a regular part of the family routine. Do not even skip one day. Third, the parents should remember that they are not alone. If they are having problems, they should ask the clinic staff for advice.

About Outcomes

Expected outcome of Ponseti Management

Feet treated by this management have been shown to be strong, flexible, and pain free, allowing a normal life [C]. If only one foot is affected, it is slightly shorter and narrower than the normal foot. The affected leg may be a little shorter than the normal leg. In most situations, all of this makes no difference.



Screening and Diagnosis

The strategy for early diagnosis of the clubfoot in Uganda depends on nurses, midwives, immunization staff, and others screening for foot deformities at birth or initial immunization with a visual foot inspection.

Screening

Screening is a public health service in which newborns and infants are offered a test, the visual foot inspection [A]. This identifies those with a suspected foot abnormality [B]. Encourage all healthcare workers to perform the visual foot inspection whenever newborns or young infants contact the healthcare system, such as at birth, postnatal clinics, and immunization visits. Those identified with a possible foot deformity can then be referred to the nearest clubfoot clinic.

In-hospital births About 40% of deliveries occur in health facilities. Nurses and midwives routinely do an examination of the newborn, ideally about an hour after a normal delivery.

Home births These are attended by traditional birth attendants. Encourage the attendants to routinely perform screening exams.

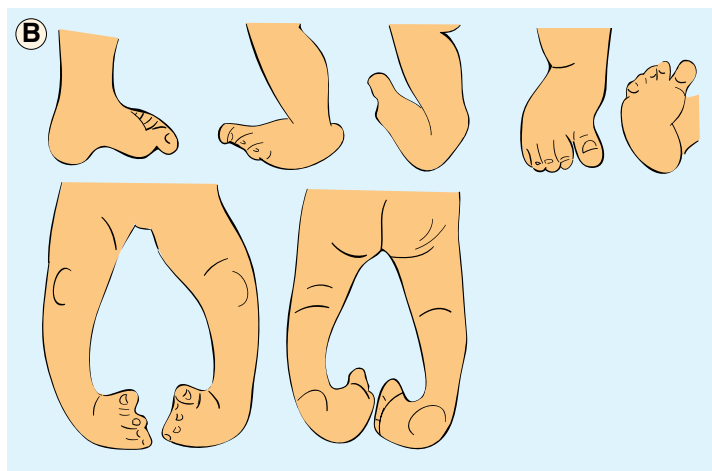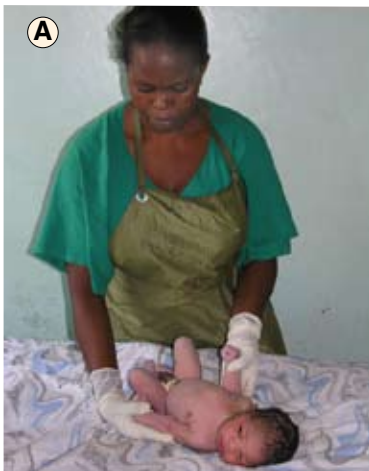Immunization All infants should receive immunization. In some areas immunization rates exceed 90%. Immunization is an ideal opportunity to screen for foot deformities.

Visual Foot Inspection

Be aware that foot abnormalities [B] occur in about 1–3% of newborns. Many are benign and may resolve without treatment. Some, such as clubfoot, are not benign and require early treatment to avoid a lifetime disability.

Perform the visual foot inspection [A] as part of the examination of the newborn. This is a critically important step in clubfoot management in Uganda. This means that all infants should be screened for foot deformities at birth. Any infant with a foot deformity should be referred for assessment and treatment by an orthopaedic officer at a clubfoot clinic. Seeing a real clubfoot in an orthopaedic clinic is the best preparation for becoming a skilled screener.

Counseling of parents Reassuring parents that most foot deformities are easily corrected if treatment is begun early helps to build confidence. Involve the whole family, especially the father. Encourage both parents to go to the clubfoot clinic with their child, allowing both to participate in decision making. Posters with this message can be helpful [C].



Diagnosis of Clubfoot

At the first consultation in the clubfoot clinic, the orthopaedic officer performs a complete history and physical exam.

Diagnosis of the clubfoot The finding of the four classic features of cavus, adductus, varus and equinus confirms the diagnosis of clubfoot. The mnemonic CAVE describes these features:

Cavus is an increase in the height of the medial arch of the foot [B].

Adductus is medial deviation of the distal part of the foot [D].

Varus is a medially deviated heel and is best observed from behind [C].

Equinus is downward pointing of the foot at the ankle [E].

Clubfoot type and score Once a diagnosis of clubfoot is made, classify its type and determine the amount of deformity (score) present in the foot (page 22). This information helps to guide treatment and reassure parents about the treatment plans.

Incidence Project data indicate the incidence of clubfoot in Uganda is 1.2 per thousand live births. Boys are affected three times more than girls. Clubfoot is bilateral in about half of the cases.

Etiology Clubfoot occurs due to a combination of genetic and environmental factors. Clubfoot sometimes runs in families. Emphasize to caregivers that clubfeet are not caused by evil spirits, witchcraft, curses, or the mother's misdeeds. If a family has one child with a clubfoot, the risk in subsequent siblings is about 30 times higher than average.

Assessing the Whole Child

The orthopaedic officer (as the primary healthcare provider) is responsible for the care of the whole child. This includes a full assessment to make certain no other conditions are present. Examine the infant by performing the following steps.

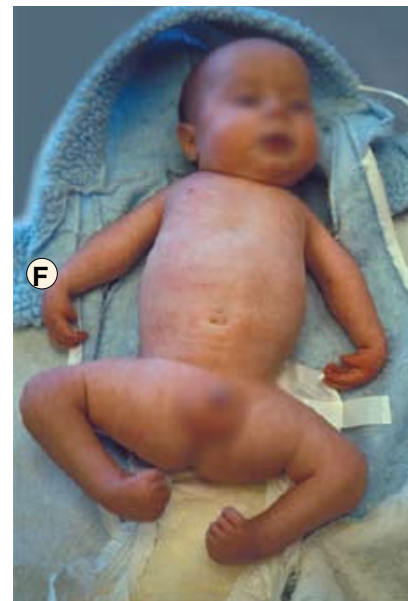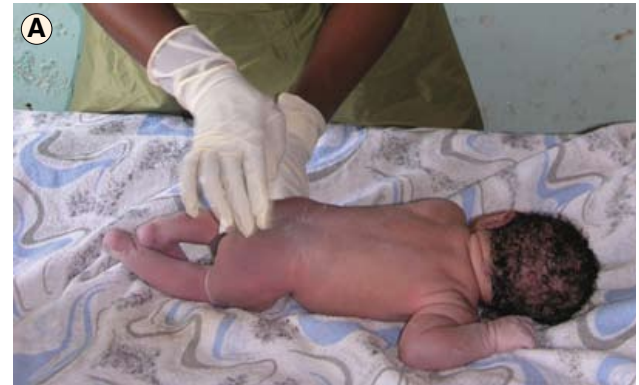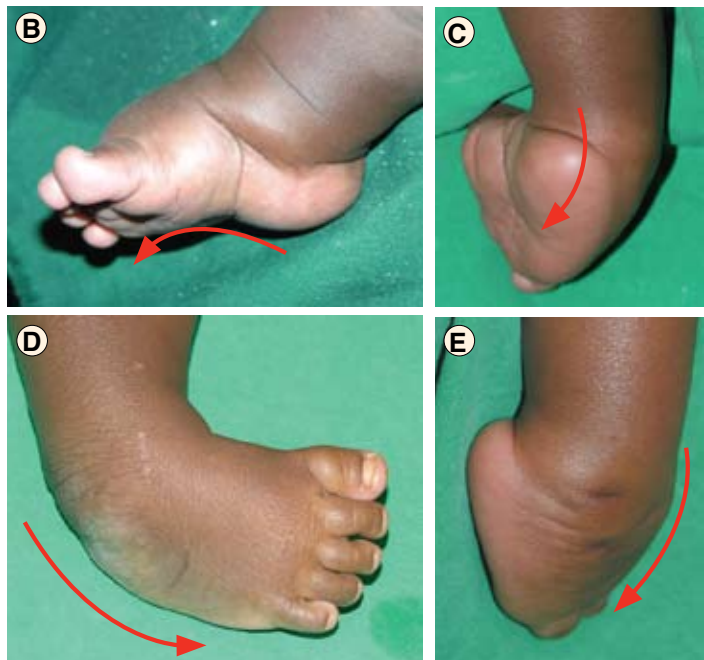
General and musculoskeletal physical exam

Examine the cardiovascular, respiratory, gastro-intestinal, genito-urinary, and central nervous systems. Examine the spine, upper extremities, hips, and feet. Finding other congenital abnormalities, such as spina bifida (an open spinal cord) [A], or arthrogryposis (multiple joint contractures) [F] suggest a syndrome. Refer to a pediatrician as appropriate. Syndromic clubfeet can be more difficult to correct. The long-term outcome is more determined by the syndrome than the foot deformity.

The management of other deformities may complicate clubfoot management. For instance, should hip instability be found, it should be managed before starting clubfoot management.

Forms

The Project suggests using a standard form [page 24, A and B] in all clubfoot clinics. This facilitates capturing all necessary data regarding the child and the deformity and its treatment.



Clubfoot Assessment

It is useful to classify a clubfoot when first seen to determine prognosis. Once classified, a clubfoot does not change its classification. Three classes of clubfeet can be determined at birth.

Congenital idiopathic clubfoot is the typical clubfoot. No other major abnormalities are present. It generally corrects in five casts [C]. With treatment, long-term outcomes are usually good or excellent.

Syndromic clubfoot Other congenital abnormalities are present. The clubfoot is part of a syndrome. Ponseti management remains the standard care, but may be more difficult, and response may be less predictable. The final outcome may depend more on the syndrome (such as arthrogyriposis) than the clubfoot.

Positional clubfoot At birth, the foot looks like a clubfoot, but is much more flexible. It occurs because of intrauterine crowding. The prognosis is excellent. It corrects with one or two casts. Braces, if used, can usually be discarded much sooner, as relapse is hardly ever a problem.

The Pirani Clubfoot Score

Definition

The Pirani Clubfoot Score measures the amount of deformity in the clubfoot. Six clinical signs seen in all clubfeet that change in severity as the foot deformity changes are each scored 0 (normal), 0.5 (mildly abnormal) or 1 (severely abnormal). They create a simple scoring system [opposite page]. Score each clubfoot every visit and record the finding on the form [page 24]. Scoring the foot at every visit helps tell the treating practitioner if deformity is correcting satisfactorily and when achilles tenotomy is indicated.

Interpretation

Scores and graphs are part of the patient's notes. Clinicians and parents can readily monitor the progress of treatment, and attend to specific areas of concern as the need arises.

Examples

Typical clubfoot [C]

At week 1, the foot had a HS (in green) of 3, a MS (in blue) of 3, and a TS (in red) of 6.

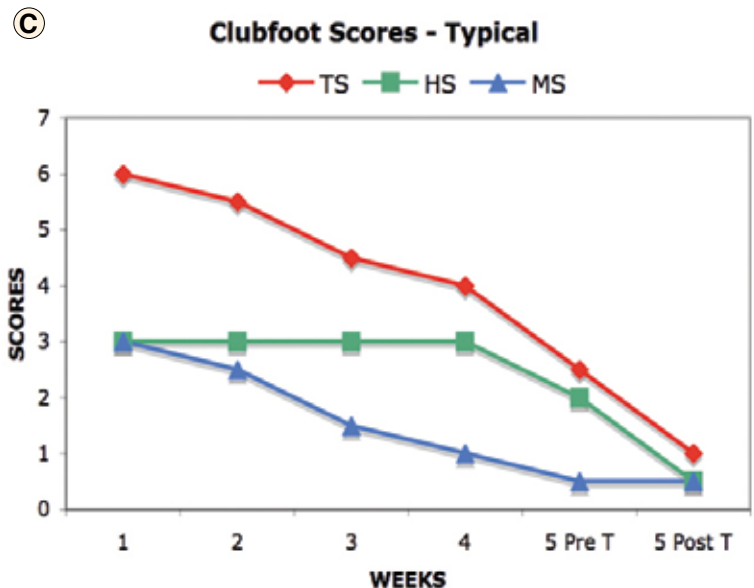
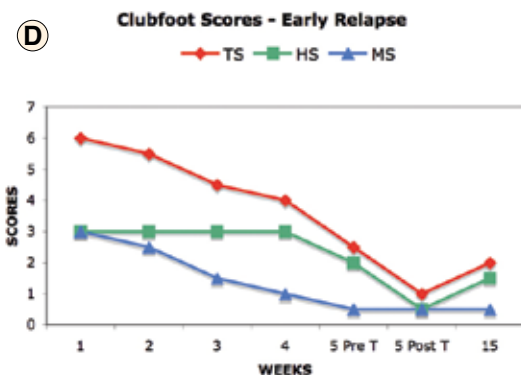
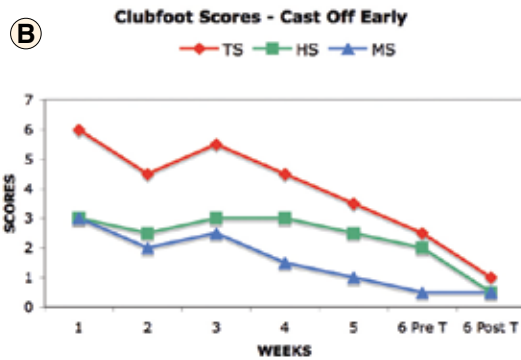
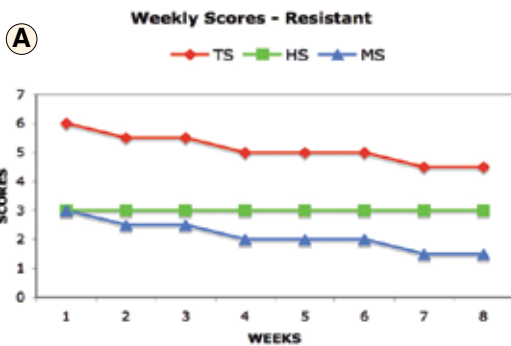
At weeks 2, 3, and 4, HS remained 3, MS improved week by week to 1, and TS improved to 4.

At week 5 before tenotomy, midfoot pathology is corrected (MS 1 or less) and hindfoot pathology persists (HS greater than 1). Achilles tendon tenotomy is performed to correct the hindfoot pathology. After tenotomy HS improved to 0.5, MS remained at 0.5, and TS improved to 1.

Resistant clubfoot [A] All scores drop very slowly.

Cast removal early [B] Scores rebound up during cast treatment if cases are removed before the clinic visit

Early relapse [D] Scores rebound up during brace treatment if bracing is inconsistent.



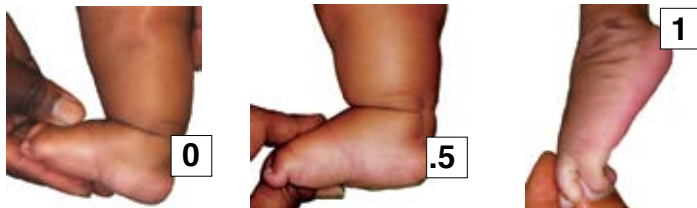Scoring

The Total Score (TS)

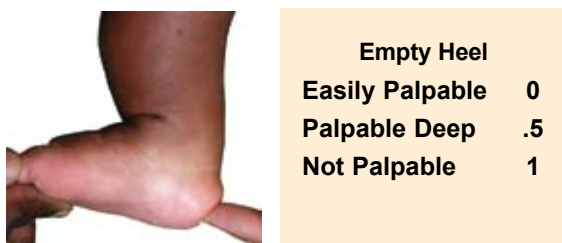
This is the sum of the HS and MS and indicates the amount of deformity overall. Values can range from 0 (no deformity), to 6 (severe deformity).

The Hindfoot Score (HS)

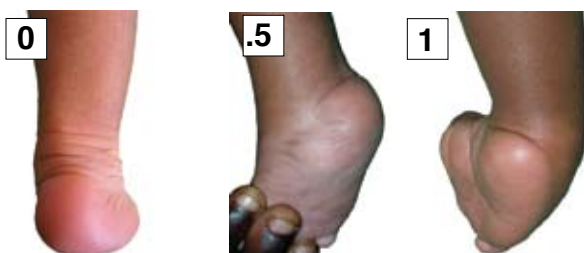The amount of hindfoot deformity is measured as the Hindfoot Score and is the sum of three signs (posterior crease, rigid equinus, and empty heel). Values can range from 0 (no deformity), to 3 (severe deformity).



Rigid Equinus (RE) Gently extend the ankle with the knee extended. The normal ankle extends at least 15 degrees beyond neutral and scores 0. With posterior contracture, ankle extension is limited. Extension only to neutral scores 0.5. Extension short of neutral scores 1.



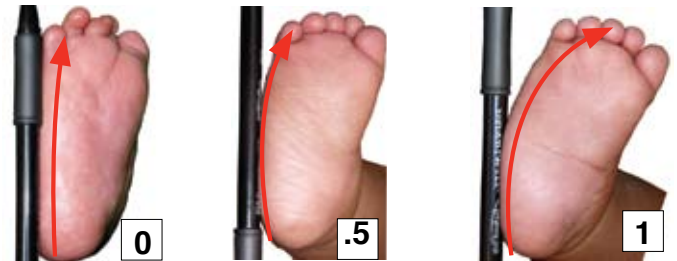Empty Heel (EH) Gently extend the ankle without hurting the child. Place a finger at the corner of the heel and feel the fat over the calcaneal tuberosity. The calcaneus is normally immediately palpable [score 0]. With posterior contracture, the calcaneus is drawn up and out of the heel pad, and the fat feels soft on palpation. A calcaneus that is palpable only deeply within the heel pad scores 0.5. A calcaneus that is not palpable scores 1.



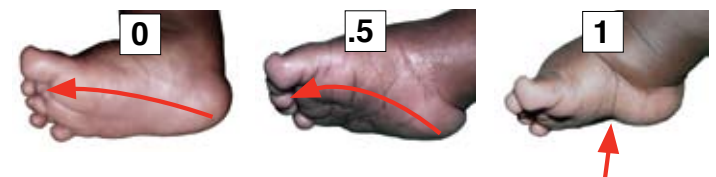Posterior Crease (PC) The normal posterior ankle skin shows multiple fine creases and scores 0. Deeper creases imply more posterior contracture. A posterior heel with one or two deeper creases scores 0.5. The presence of a single deep crease that changes the contour of the heel scores 1.

The Midfoot Score (MS)

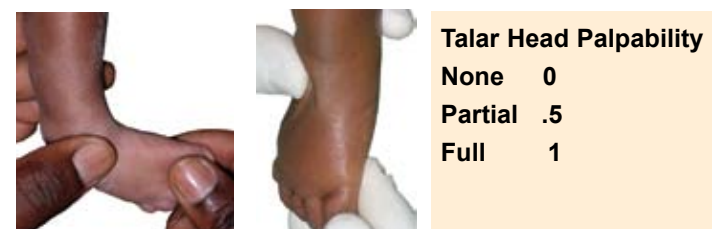
The Midfoot Score measures midfoot deformity and is the sum of three signs (medial crease, curved lateral border, and lateral head of talus). Values can range from 0 or (no deformity), to 3 (severe deformity).



Curved lateral border (CLB) A normal foot has a straight lateral border and scores 0. Adductus causes a curved lateral border. A mild curve, where the lateral border curves at the metatarsals, scores 0.5. A lateral border that curves at the level of the calcaneo-cuboid joint scores 1.



Medial Crease (MC) A normal arch displays multiple fine skin lines and scores 0. Mild medial contracture causing one or two deeper creases that do not alter the arch's contour scores 0.5. A single deep crease indenting the arch's contour suggests severe medial/plantar contracture and scores 1.



Lateral Head of Talus (LHT) Estimate the amount of uncovered talar head laterally [page 17, B] as an indicator of midfoot pathology. Hold the foot deformed and palpate the head of the talus with the thumb. Abduct the foot with the other hand. Note if the navicular reduces onto the head of the talus. Normally, abduction reduces the navicular completely to the talar head which is no longer palpable and scores 0. With medial contracture, the navicular does not fully cover over the talar head. A talar head that partially covers but remains somewhat palpable scores 0.5. A talar head that does not cover at all and remains easily palpable scores 1.

Overview of Management

There are four steps in the overall management of the child with a clubfoot.

Step 1 – Screen for foot deformities

Encourage all healthcare workers [A] at birthing and immunization centers to screen all newborns and infants for foot deformities and then to refer those with possible abnormality for assessment and treatment by an orthopaedic officer at a clubfoot clinic. This lessens the risk of those born with clubfeet escaping early diagnosis.

Step 2 – Confirm diagnosis of clubfoot

The orthopaedic officer makes or refutes the diagnosis of clubfoot at the first visit to the clubfoot clinic.

Step 3 – Correct by casting and tenotomy

Once diagnosed, treat with the Ponseti Method – usually five casts are sufficient [B].

Correct cavus by holding the supinated forefoot in proper alignment with the hindfoot. Start abducting the foot – often the foot comes into some abduction. Cast 1 corrects cavus and can correct some adduction.

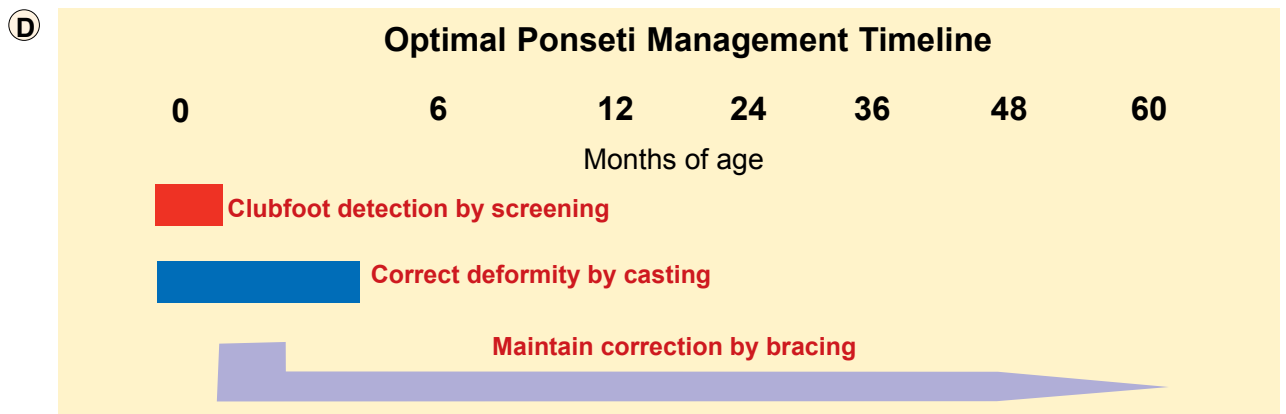
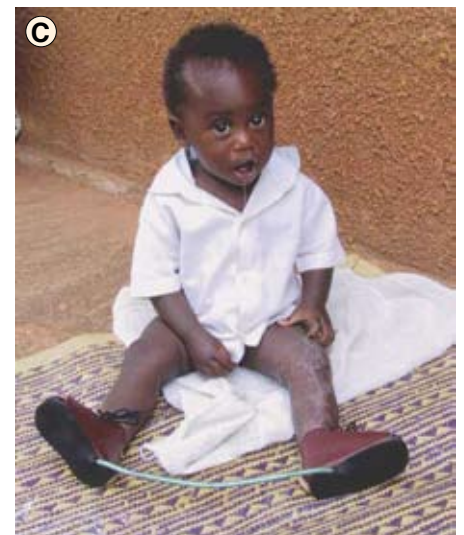
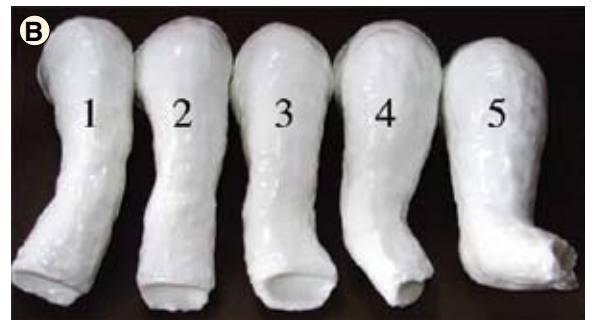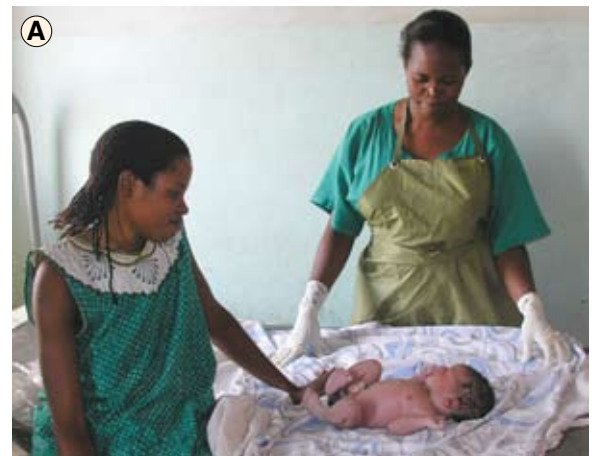Correct adduction and heel varus by holding the entire foot in gradually increasing abduction under the talus with casts 2, 3 and 4. Heel varus will correct when the entire foot is fully abducted.

Correct equinus with percutaneous tenotomy of the tendo achilles as needed and then holding the foot dorsiflexed and in full abduction with cast 5.

Step 4 – Prevent relapse of deformity by bracing

The purpose of the Steenbeek foot abduction brace [C] is to prevent relapse of deformity by holding the foot in the corrected position. Its use full time for 3 months and at night-time until 4 years of age is critical for the success of the treatment program.

Follow-up is essential, as management extends over several years [D]. See the infant and family at regular intervals to identify problems with the use of the brace to prevent problems that might lead to noncompliance.



Clubfoot Clinics

A network of clubfoot clinics are the focal points of care of the child with a clubfoot. The typical clubfoot clinic will be in a general hospital or regional referral hospital for a half day each week in the plaster room.

Volume

Expect about one to three new infants a week referred with foot deformities. Many will have positional foot deformities not requiring any more than reassurance. Twenty-five to 50 infants born each year will need care for clubfeet – half will have both feet affected. Therefore plan corrective casts for between 40 to 70 feet per year. Adjust numbers according to experience.

At each weekly clinic 5 to 10 patients will be there for consultation, manipulation and casting, tenotomy, or first-time brace application (20–30 minutes each), and 10 to 20 patients will be there for brace check and review for relapse of deformity (10–15 minutes each). Clinic numbers will grow for four years before reaching a steady state, as each child will be seen for at least four years.

Staffing

There will be enough work for two orthopaedic officers. They should have quick access to a medical officer or a surgeon for tenotomies.

Typical materials/supplies for 70 feet per year

Cotton padding Order 1500 six-inch rolls of padding.

Plaster Order 1200 six-inch plaster rolls. Each foot will require 3 six-inch rolls for each cast.

Recurrent clubfeet About 10% of clubfeet will recur. Each recurrent clubfoot will need between 15 and 30 rolls for correction, depending of foot size and severity of relapse.

Tenotomy supplies Most feet will come to achilles tenotomy. Use a new set on each foot (unless performing bilateral tenotomies at the same sitting). Occasionally tenotomies are needed for relapse. Prepare 70 sets annually.

Steenbeek foot abduction splints Each child will need up to 8 braces (sizes 6 to 13) during treatment. Reuse braces when possible. Order 30 complete sets the first year. Then adjust according to patient volume and experience.

Patient visit protocol

Advise caregivers that about 20 visits over four years leads to optimal outcomes.

Corrective phase usually requires 7 visits – 5 weekly visits for five casts, a 6th visit 3 weeks later for removal of cast and fitting of a SFAB, and a 7th visit 2 to 4 weeks later for a brace-wearing compliance check.

Maintenance phase See the patient every 3 months up to walking age, and then every 6 months until the fourth birthday. At each visit, assess for relapse and fitting of the brace. Determine if the brace is being worn. Children with muscle imbalance will need longer follow-up and more visits.

Patient flow

Clubfoot management involves many steps. At many clubfoot clinics, staff organize “stations,” where clinic activities are performed. Teaching posters outline the nature of activities at each station [opposite page].

Assessment At the first visit confirm or refute a diagnosis of clubfoot. Children with other orthopaedic problems should be directed to the general orthopaedic clinic.

Classify the type of clubfoot at the first visit and examine for other congenital anomalies. If present, refer also to other appropriate clinics (such as the spina bifida clinic).

Measure Pirani Score for every clubfoot at every visit. It guides the treatment plan for the visit.

Manipulation and casting Correct the cavus, adductus, and varus components of the deformity with manipulation and casts 1 to 4.

Tenotomy When indicated by the Pirani Score, call the doctor to correct the equinus component of the deformity by achilles tenotomy.

Bracing Prevent relapse by fitting and ensuring continuing use of a well-fitting Steenbeek foot abduction brace. Watch for relapse and manage nonoperatively if it occurs. Refer relapse not responding to nonoperative methods to an orthopaedic surgeon for re-evaluation.

Visit checkout Check the foot and cast or brace at the visit checkout. Arrange follow-up.

Clubfoot Clinic Roles

Clubfoot clinics may also have teaching and research roles.

Educational role

All nursing, midwifery, and (para)medical students who come into contact with newborns and infants will benefit from a rotation in their training by attending a local clubfoot clinic to learn about clubfeet and their management.

Teaching posters detail the treatment at all stations [opposite page]. Following infants through each treatment station allows healthcare workers to understand the theory and practice of each step in treatment.

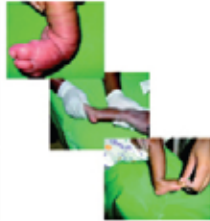Research role

Clinics collect data for clinical care. These data can also be used for program administration and research.

Patient Flow

1. Assess:
 - > The whole child (new case)
 - > Muscular-skeletal system (new case)
 - > The old cast (follow-up cases)
 - > Amount of deformity (both new and follow-up cases)
2. Confirm the diagnosis of clubfoot. If not clubfoot, refer to appropriate clinic.
3. Classify the type of clubfoot
4. Record condition of cast/braces
5. Counsel parents and obtain consent (new cases)
6. Send to next station:

Manipulation & Casting	HFC present (Equinus) MFC present
Tenotomy	No MFC HFC present
Bracing	No MFC present No HFC present



Assessment Station



1. Prepare everything you need before starting M & C
 - > 3 shoes
 - > CRT
 - > materials
 - > mother/baby breastfeeding
 - > position of manipulator/assistant

2. Manipulate the foot gently without hurting the child
 - > Roles of manipulator & assistant



3. Apply the appropriate cast to maintain correction

> Sequence:

> Moulding:



> Bk first:



4. Check

> Circulation
> Cast for expected position and completeness

5. Give instructions to the parent:

> To avoid wetting or soiling the cast
> To observe for complications like: Swelling/Change of color of toes. Excessive crying.
> To come back immediately if he/she notices one of above mentioned features

6. Send to final checkpoint.

Casting Station



Bracing Station

Child ready for braces:
> When HFC & MFC corrected

1. Explain, educate the parent about the importance of the brace
 - > Loosen shoelaces or remove them completely. Fit the brace; the "difficult" foot first, as the parent observes.
 - > Gently dorsiflex the foot as much as possible. Hold it in that position with one hand and then push the foot (heel first) in the brace.
 - > Close the tongue of the shoe and check whether heel is still in correct position by looking through the inspection hole. Keep the foot in position with the same hand and lace the shoe with the other hand.
 - > Now fit the other foot in the same way
 - > Check that the heel is down in the shoe through the hole.
2. Remove the brace and let the parent fit. Let him/her repeat till comfortable doing it.
3. Give instructions to the parent:
 - > Full time bracing for 3 months, remove only for bathing
 - > Keep on checking several times per day, whether the heel is still visible through hole.
 - > After 3 months bracing only at night for up to 4 years of age.
 - > Keep brace clean and dry at all times
 - > Do not let child stand on bar
 - > Check shoe whether it is still fitting
 - > When child cries more than usual check the foot for red spots or blisters. Brace may be getting too small.
 - > Report to clinic in case of problems or as per appointment
4. Send to final checkpoint



!!!! Indication: LHT score = 0 DF < 10°, Heel in valgus

1. Set tenotomy table with:
 - > Clean linen
 - > Antiseptics
 - > Surgical gloves
 - > Syringes, 2ml
 - > Local anaesthetic, lignocaine 2%
 - > Blade handle
 - > Surgical blades, size 15"
 - > Sterile gauze
 - > Cotton wool
 - > POP
 - > Water
2. Organize 2 people: 1 Doctor, 1 IO
3. Carefully explain the procedure to the parent
4. Hold the knee in full extension and the foot in dorsiflexion in neutral position to make the tendon taut and palpable.
 
5. Tenotomy is done by surgeon/medical officer.
6. Cast the foot in maximum abduction and dorsiflexion. The knee should be at 90°
 
7. Check circulation
8. Send to final checkpoint

Tenotomy Station



Visit Checkout

A. In a casted foot check:

- 1) Completeness
- 2) Position achieved
- 3) Circulation
- 4) Parent understanding



B. In a braced foot check:

- 1) Heel down
- 2) Parent understanding
- 3) Next appointment



C. Make new appointment for next visit

Casting Setup and Technique

These two pages show the general steps in cast application common to all casts. Pages 30–31 describe the specific steps for each individual cast. We suggest using these steps every time. The process will soon become second nature, and better results will be achieved.

Materials

Preparing and setting up before the clinic starts makes materials easily available during casting. The clinic will thus run more smoothly.

Cast cart A mobile cast cart, available from the orthopaedic workshop at Katalemwa, holds all supplies and a low platform for a bucket of water [A]. It is on wheels and can be moved as needed. Supplies can be easily reached throughout the casting procedure.

Supplies The supplies needed during manipulations and casting are listed in the table of materials for casting [B].

Attitude

Be kind, sensitive, and reassuring to the family and infant. Emphasize that treatment will be successful and the infant's deformity will be corrected. Use the casting time to explore problems the parents might have or to answer questions. Help the family to understand the overview of management and the importance of each step. Allow the mother to breast-feed, which calms the infant during the procedure. Everyone will be more at ease if the child is happy. Watch the child's face for signs of discomfort. If the infant appears distressed, encourage breastfeeding. If this is not successful, slow down, reduce the pressure, and allow the infant to become calm. Do not hurt the infant. This should be a painless procedure.



B Material for Casting
1. Cotton undercast padding
2. Plaster of Paris bandages cut to 2 – 3-inch size
3. Bucket of water
4. Plastic apron
5. Plaster scissors for trimming edges of the cast
6. Surgical blade #24
7. Cloth for clean up
8. Disposable gloves

Communication with parents

Take a moment to teach the parents about foot and cast care before they leave the clinic. Reassuring and encouraging words help the caregivers to feel that the treatment will have a beneficial outcome. Ask the parents to regularly observe for signs of trouble.

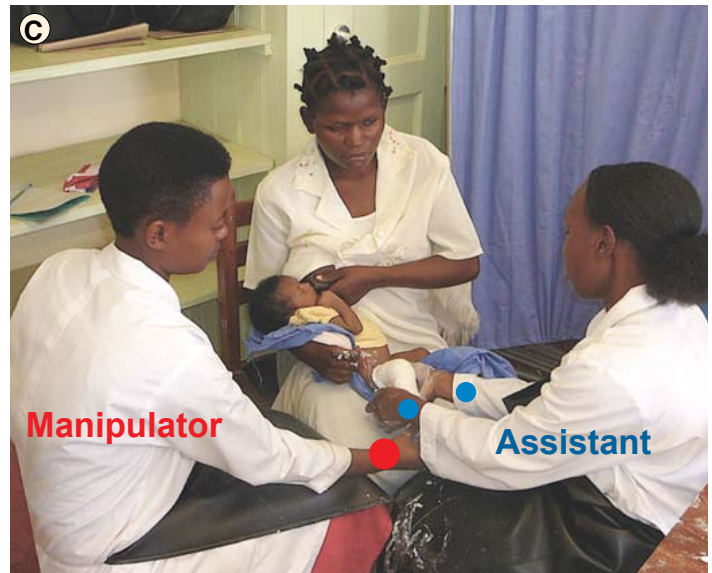Toes change color/swell and baby cries Caregivers should soak the cast, remove it, and bring the infant back to the clinic.

Cast gets wet This irritates the skin. The cast becomes too weak to maintain the foot in good position. Caregiver should bring the infant back to the clinic as soon as feasible.

Positioning

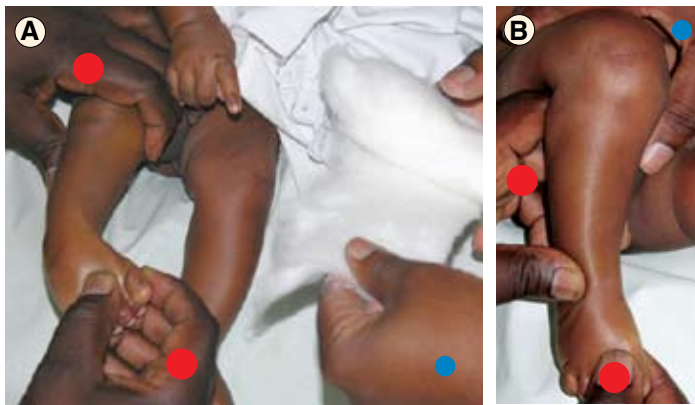
Manipulator and assistant Both sit facing the affected foot [C]. With respect to the affected foot, the manipulator sits laterally and the assistant sits medially.

Infant in mother's lap Position the infant across the mother's lap to allow the infant to breast-feed before and during the casting [C]. When casting the right foot, the infant's head should be near the mother's right breast. Reverse the position when casting the left foot.

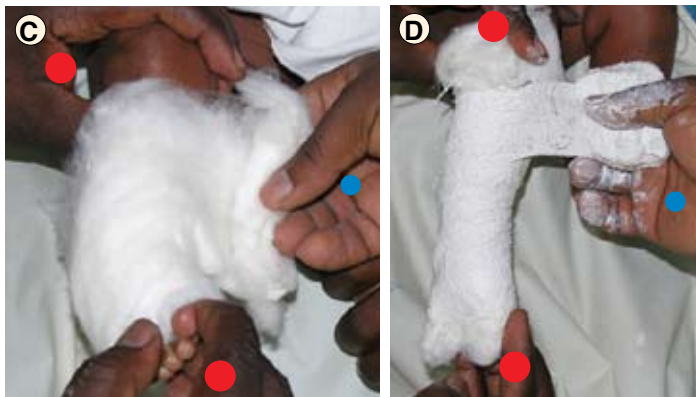


Cast Technique

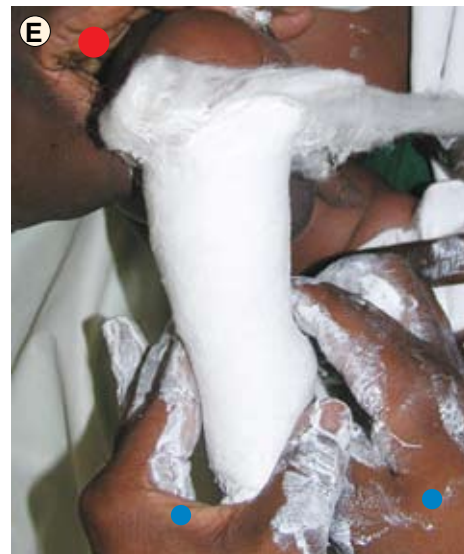Casting requires two skilled persons – a manipulator and an assistant – and preferably the mother to hold the infant in her lap. All should be seated. People and hands in the pictures are identified by a red dot for the manipulator and a smaller blue dot for the assistant. Differentiating the roles helps in learning positioning and hand technique. The manipulator manipulates the foot to correct the deformity as much as possible without hurting the infant [A and B], and then holds the foot in the improved position while the assistant applies the padding [C] and then the cast [D]. Once applied, mould the cast as it sets to maintain the foot in the correct position [E]. Extend above the flexed knee [F and G] and trim [H]. These techniques are fully described on pages 30 and 31.



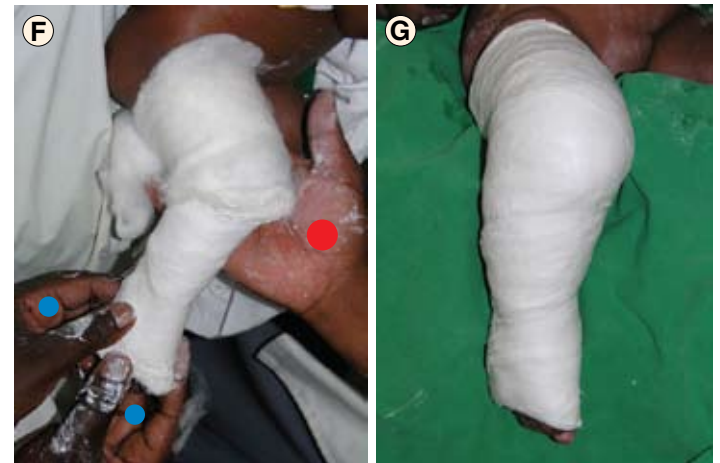Manipulate foot and hold The manipulator gently corrects the deformity as much as possible (without hurting the child) to stretch medial and plantar soft tissues [A and B]. A mental note is made regarding the position achieved.



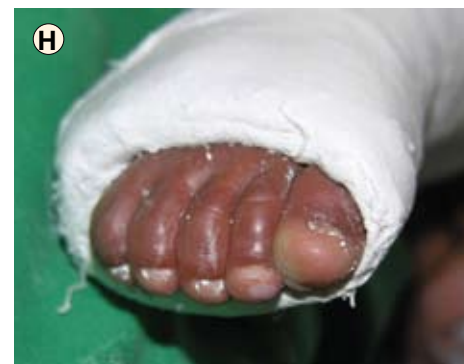Apply below-knee padding and cast The manipulator holds the foot in position. The assistant applies thin (about 0.5 cm thick) padding over foot and leg from the tips of the toes to just below the knee [C]. Beginning with the toes, the assistant applies 4-5 layers of plaster distal to the knee [D]. Excessive layers make moulding difficult.



Mould cast The manipulator stabilizes the knee while the assistant moulds the cast to hold the foot in the corrected position [E]. The assistant's hands and fingers move continuously to reduce the risk of pressure sores while the plaster sets.



Extended cast above knee The cast is extended above the flexed knee (90 degrees) to avoid the possibility of the cast slipping off the leg [F and G].



Trim cast The cast is then trimmed to remove excess plaster to leave the toes uncrowded and yet supported [H]. Clean the child.

Ponseti Corrective Casts

Most clubfeet correct with about five casts. The first cast corrects the cavus. Subsequent casts correct the adduction and varus by progressively abducting the foot. The last cast in combination with tenotomy corrects the equinus.

There are three phases to applying each cast: manipulation, applying padding and plaster, and moulding after the cast is applied. Different hand positions are required for each phase. An effective method is shown. Use this method until experience is gained. Once you are experienced, you may prefer to consider using one of several alternative hand positions as shown on page 47 [E, bottom picture].

Correction of Cavus – First Cast

The text and pictures describe the technique for a right clubfoot. Reverse hands for a left clubfoot. Cavus is due to the pronation of the forefoot in relation to the hindfoot, which is supple in newborns. Elevating the first metatarsal usually restores a normal longitudinal arch to the foot. Therefore, correct cavus by elevating the first metatarsal to position the forefoot in proper alignment with the hindfoot and apply cast 1. Correct alignment of the forefoot with the hindfoot is necessary before correcting the adductus and varus.

Manipulation

The manipulator uses both hands to position the foot.

Exactly locate the head of the talus Palpate the right lateral malleolus with the thumb of the left hand while the toes and metatarsals are held with the other hand. Next, slide the left thumb forward about 1 to 1.5 cm to palpate the head of the talus. The lateral part of the talar head is barely covered by the skin in front and is easily felt.

Elevate the first metatarsal The manipulator's right hand gently grasps the foot at the first metatarsal head and elevates it for about 30 seconds to stretch the plantar tissues [A]. Start abducting the foot — often the foot comes into some abduction. Cast 1 corrects cavus and can correct some adduction.

Apply cotton wool and plaster

With the foot in the corrected position, the manipulator's left hand moves up the leg to be out of the way of the cotton wool. Correction is maintained by gentle left thumb pressure over the upper leg. The manipulator's right hand continues holding the forefoot in the corrected position while the assistant applies the cotton wool [B]. As the padding and then the cast is applied, the first few wraps go over the manipulator's fingers. As the wrapping/cast moves proximally, the manipulator's right thumb comes out from under the wrap and helps to hold the foot in good position by applying some pressure to the talar head laterally [C]. The assistant applies a below-the-knee cast [D] as the manipulator continues holding the foot in the corrected position in the same fashion as for wrapping the cotton wool.

Mould cast

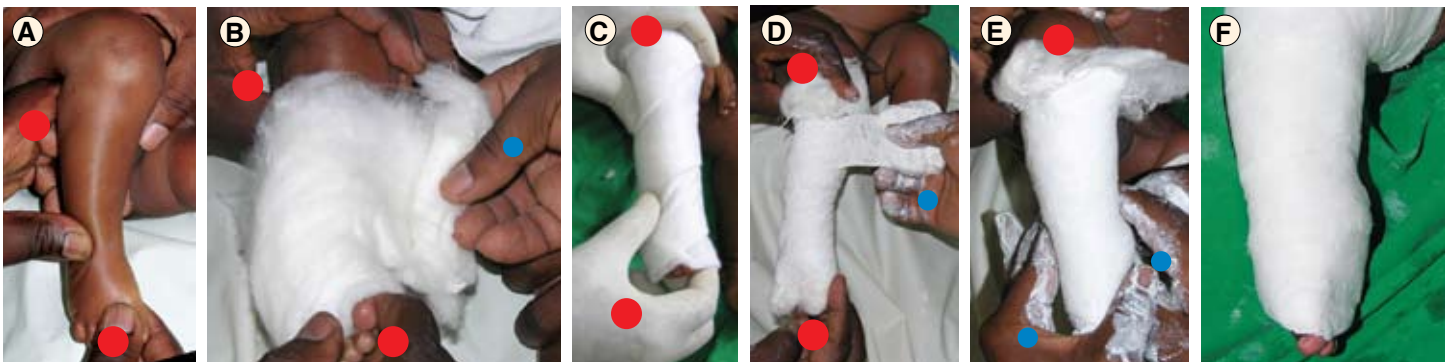
The assistant uses the left hand to hold the foot. The left thumb elevates the first metatarsal and moulds the arch. The left index finger (constantly moving to avoid creating a dent in the cast) applies pressure over the head of the talus. The right index finger moulds above the calcaneus and around the malleoli [E].

Extend above knee

Once the lower section is set, the upper part of the cast is applied with the knee in 90 degrees of flexion. Take care not to externally rotate the lower extremity through the knee. The cast is applied up to the groin.

Cast appearance

The first cast corrects the cavus deformity. A gentle depression is seen just above the heel posteriorly. This prevents the heel from moving proximally in the cast. The plantar surface is moulded flat. The ankle remains in marked equinus. The foot is supinated [F]. Compare to the model of the first cast [next page, D].



Correction of Adduction and Varus – The Second, Third, and Fourth Casts

The text and pictures on this page describe the technique for a right clubfoot. Reverse hands for a left clubfoot. Forefoot adduction is due to medial displacement of the navicular on the head of the talus and cuboid on the calcaneus. Heel varus is due to an adducted and inverted calcaneus under the talus. Both deformities are corrected by manipulating and casting the supinated foot gradually into full abduction. This correction usually requires three to four casts applied at weekly intervals [A, B, C and D]. Adduction and varus correct simultaneously.

Manipulation

For a right clubfoot, the manipulator locates the head of the talus using the left thumb [E]. The manipulator's right hand gently grasps the first metatarsal head and abducts the first metatarsal (and therefore the entire foot) while maintaining supination. The left thumb continues to apply counterpressure at the head of the talus. The medial tissues are stretched for about 30 seconds [E]. The left thumb then moves up the leg to be out of the way. It applies counterpressure at the upper leg [F].

Apply cotton wool and cast

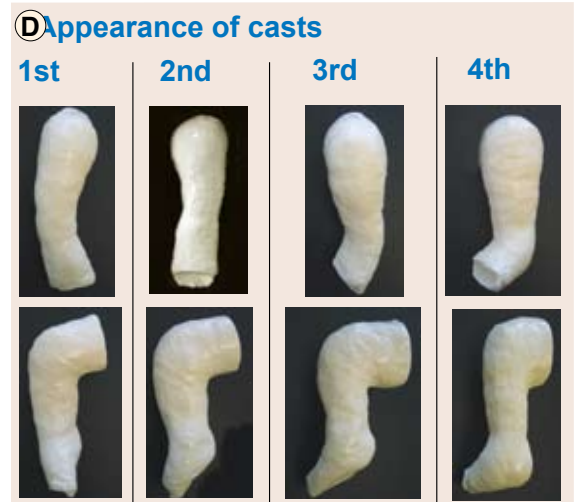
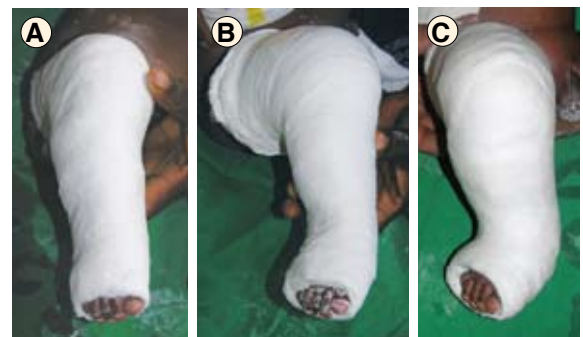
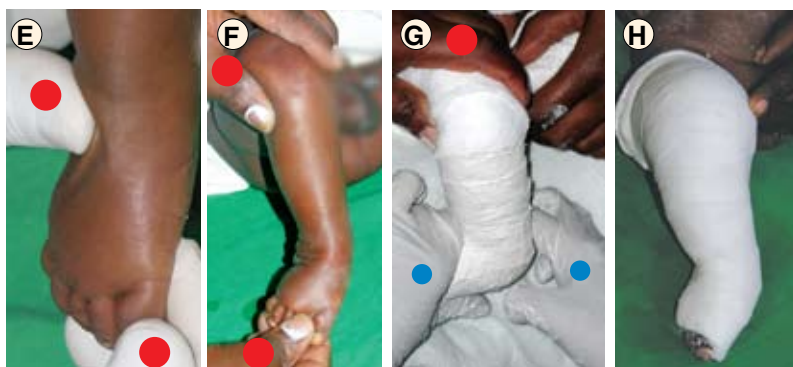
The manipulator holds the corrected position while the assistant applies the padding and cast. As with the first cast, the padding is thin and precise about the foot and thicker on the leg. The padding is wrapped over the fingers holding the forefoot. A below-the-knee cast is applied [G].

Mould cast

The assistant uses the left hand to hold the position of the foot while the right hand moulds around the malleoli and achilles tendon. The left thumb applies pressure over the plantar and medial sides of the first metatarsal, gently supinating and abducting the forefoot. The left index finger gently moves over the head of the talus laterally, providing counterpressure. It is very important for the right index finger to mould carefully around the malleoli and above the calcaneus [G]. These casts should fit snugly and have the appearance of the foot. If the cast is not well moulded, the foot can slip upward causing pressure sores or a secondary deformity. Extend the cast above the knee, as with the first cast [H].

Cast appearance

Each cast shows improvement. The foot progressively abducts about 20 degrees each time. After the fourth cast, full correction of the cavus, adductus, and varus are noted [C and D]. The equinus deformity also gradually improves because the calcaneus dorsiflexes as it abducts under the talus. No direct attempt at equinus correction is made. Attempting to dorsiflex the foot against a tight tendo achilles causes a rocker bottom deformity of the foot. Final correction of ankle equinus is effected by percutaneous tenotomy of the achilles tendon.



Cast Removal

Inform parents that all casts are removed in the clinic just before a new cast is applied. Correction can be lost from the time the cast is removed until the new one is placed.

Soaking cast

Soak the cast in water provided at the clinic for about 20 minutes in preparation for cast removal. This can be simply performed with buckets provided in the clinic [A and B]. Further softening of the cast may be done manually [C] to make removal easier [D].

Options for removal

The softened cast may be removed in a number of ways.

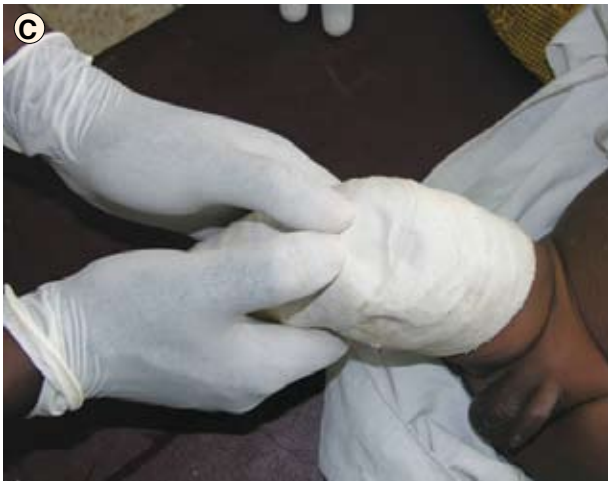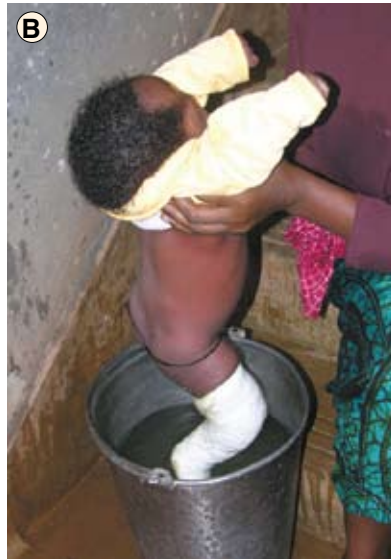Unrolling the plaster This is the most simple method but requires that the end of the plaster roll be found [D]. Finding this end may be facilitated by including it in a plaster nob when the cast is applied.

Plaster shears This method utilizes shears to remove a segment of plaster [next page, A, B and C]. As the shears encompass the cast, injury to the skin is minimized. Insertion of the shear blades is easy in the thigh but more difficult in the leg portion because of insufficient space between the cast and the skin to allow inserting the blades.

Plaster knife Plaster knives should be kept sharp and are an inexpensive and effective method for cast removal [next page, D, E and F]. Use the blade to cut obliquely to reduce the risk of cutting too deeply.

Scalpel blade Blades are often available in the clinic and convenient to use [next page, G and H]. Because they are very sharp, they must be used with caution. Hold the blade with just a small amount of the blade exposed to avoid cutting deeper than the plaster.

Electrical cast saw These are noisy, and often frighten the infant and family, and therefore are not recommended.



Technique of removal

Remove the cast in steps:

Cut the cast from the anterior or lateral aspect beginning at the groin and moving downward [A, B, and C].

Monitor the depth of the cutting edge of the blade to avoid cutting too deeply [G].

Cut only the cast, not the padding with the cast knife to avoid skin injury [G].

Remove the above-knee portion of the cast first [C].

Remove the soft padding gently to expose the skin [F].

Remove the below-knee portion of the cast last [H].

Clean the skin with water.

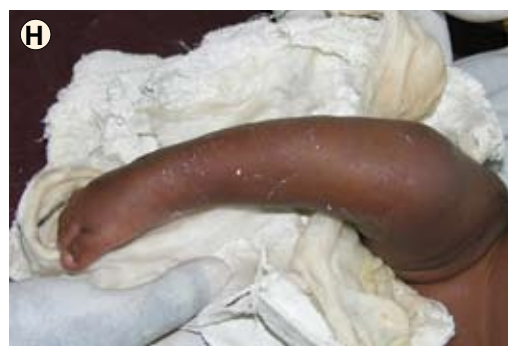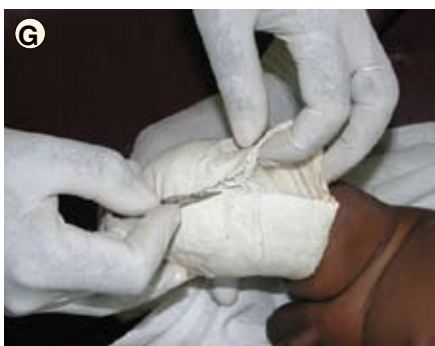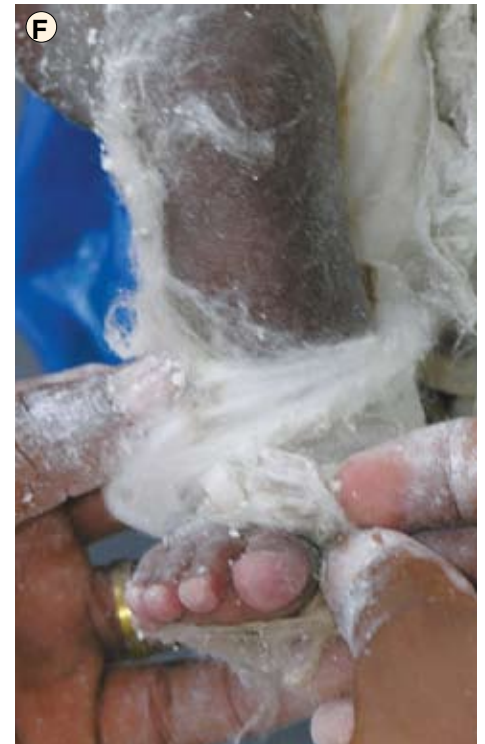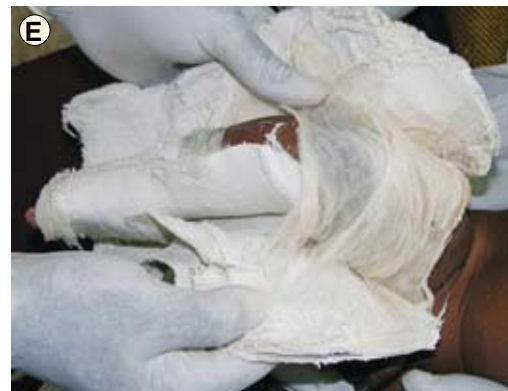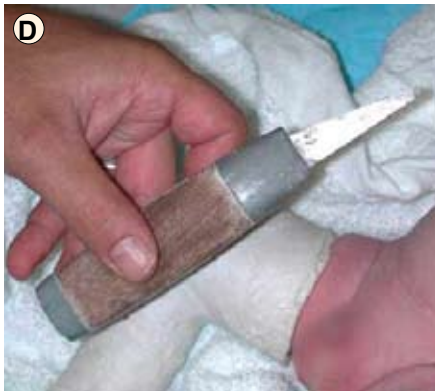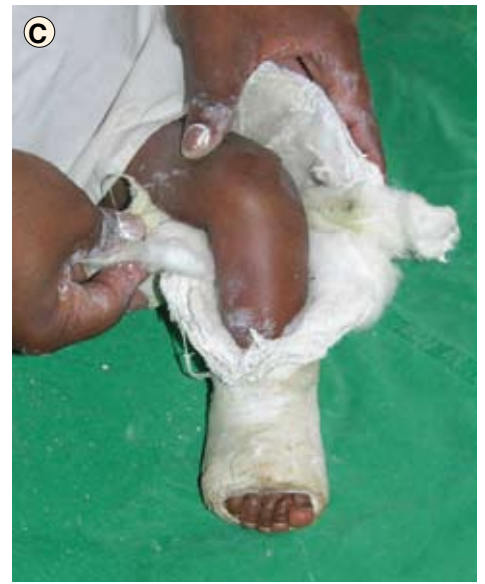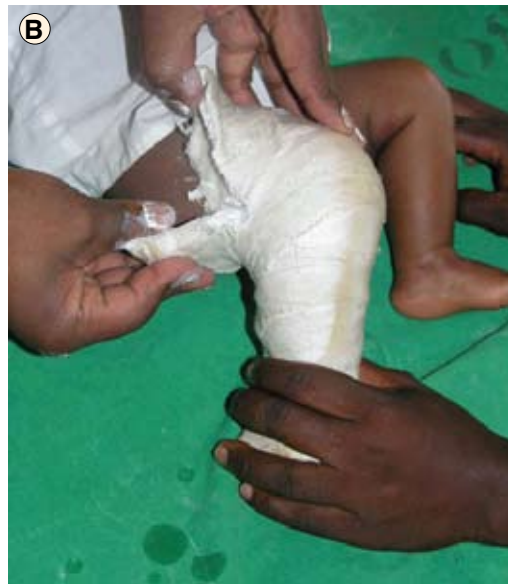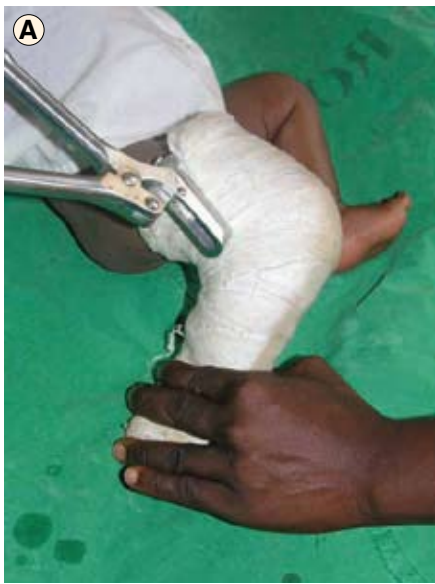Complications of Casting

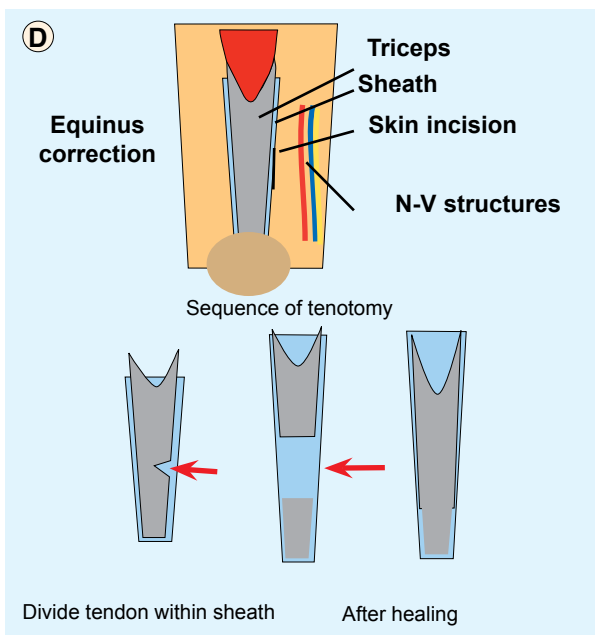
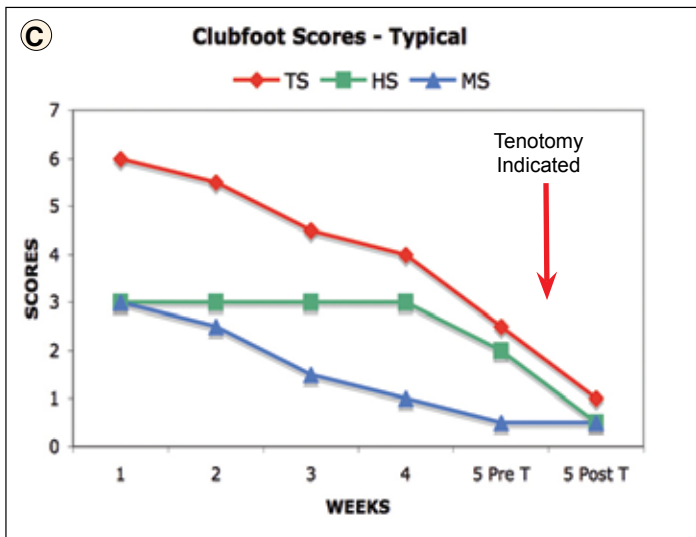
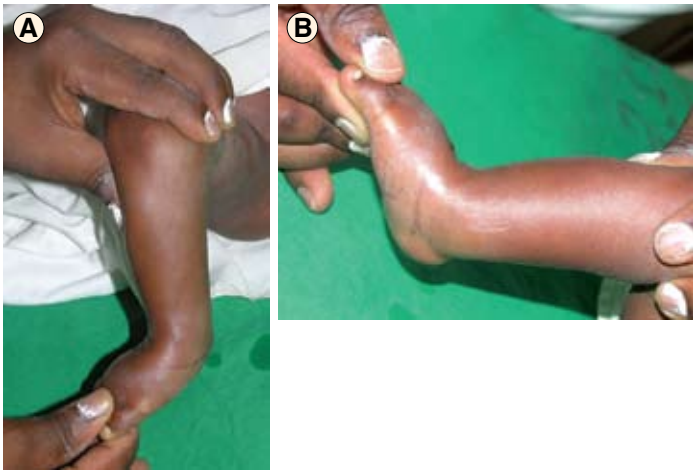
Using careful technique, as described, complications are uncommon.

Pressure sores are due to poor technique. Common sites include the head of the talus or over the heel.

Superficial sores are managed by applying a dressing and a new cast with additional padding.

Deep sores are dressed and left out of the cast for one week to allow healing. Casting is then resumed with special care to avoid relapse.





Tenotomy

Indication for tenotomy

In the Ugandan system the orthopaedic officer sees each child, examines every clubfoot and measures the Pirani Score on every visit, especially during the first year of treatment. When the examination or the Pirani Score suggest that a tenotomy is indicated, the medical officer or surgeon supporting the clinic should be called to confirm the findings and perform a tenotomy.

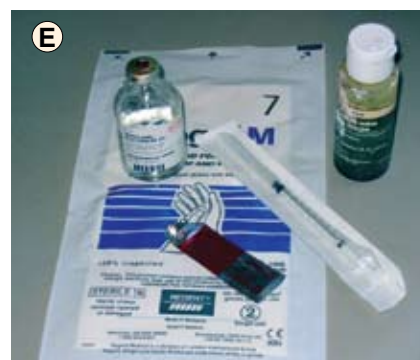Tenotomy is indicated to correct equinus when cavus, adductus, and varus are fully corrected but ankle dorsiflexion remains less than 10 degrees above neutral. There are two ways to tell if tenotomy is indicated.

Evaluate calcaneal abduction and ankle dorsiflexion The clubfoot is sufficiently corrected to proceed with tenotomy when the anterior calcaneus is abducted away from under the anterior talus. With sufficient abduction, the anterior process of the calcaneus becomes palpable laterally just plantar to the head of the talus, which becomes less palpable as it is covered by the navicular. The foot appears abducted approximately 60 or 70 degrees in relationship to the frontal plane of the tibia [A]. The heel is in neutral or slight valgus. Proceed with tenotomy if ankle dorsiflexion is less than 10 degrees above neutral [B].

The Pirani Score is a measure of midfoot and hindfoot deformity [C]. As correction progresses, the Midfoot Score (blue line in graph) corrects first whereas the Hindfoot Score (green line in graph) remains high. Tenotomy is indicated (red arrow) when the Midfoot Score is one or less and the Hindfoot Score is more than one (the Lateral Head of Talus Sign should be zero).

Preparing the family and equipment

Prepare the family by explaining the procedure. Explain that tenotomy is a minor procedure performed under local anaesthetic in the outpatient clinic. Prepare a blade. A cataract knife is best as the incision is then very small. If unavailable, other blades such as an #11 or #15 blade will work. Prepare other supplies as shown in the equipment list [E].



Equipment List

- Insulin or tb syringe
- 25# needle
- gloves
- gauze
- #11 or #15 blade
- local anaesthetic
- prep solution

Tenotomy Technique

Positioning and roles

Place the baby at the end of the examination table with the medical officer at the feet, and the orthopaedic officer to the ipsilateral side [F]. The diagram [previous page, D] shows what needs to be achieved. This is a complete section of the tendon, not a tendon lengthening. In infants, the tendon rapidly heals.

The medical officer is positioned looking at the tendon from the medial aspect and performs the tenotomy.

The orthopaedic officer acts as an assistant. With one hand, the assistant holds the limb firmly at the knee, holding the knee straight. The other hand dorsiflexes the foot to stretch the achilles tendon [A].

Skin preparation and anesthesia

The medical officer preps the foot thoroughly from midcalf to midfoot with an antiseptic [A].

The medical officer then palpates the spot where the tendon feels most prominent, usually about one to one and a half centimeters above the calcaneus. Plan on tenotomy at this point. Infiltrate a small amount of local anesthetic just medial to the tendon where it is most easily palpated [B]. Be aware that too much local anesthetic makes palpation of the tendon difficult and the procedure more complicated.

Heel cord tenotomy

Insert the tip of the scalpel blade from the medial side, directed immediately anterior to the tendon. Keep the flat part of the blade parallel to the tendon. The initial entry causes a small longitudinal incision [C]. Care must be taken to be gentle so as not to accidentally make a large skin incision. The blade is then rotated, so that its sharp edge is directed posteriorly towards the tendon. The blade is then moved a little posteriorly. A “pop” is felt as the sharp edge releases the tendon. The tendon is not cut completely unless a “pop” is appreciated. An additional 15 to 20 degrees of dorsiflexion is typically gained after the tenotomy [D].

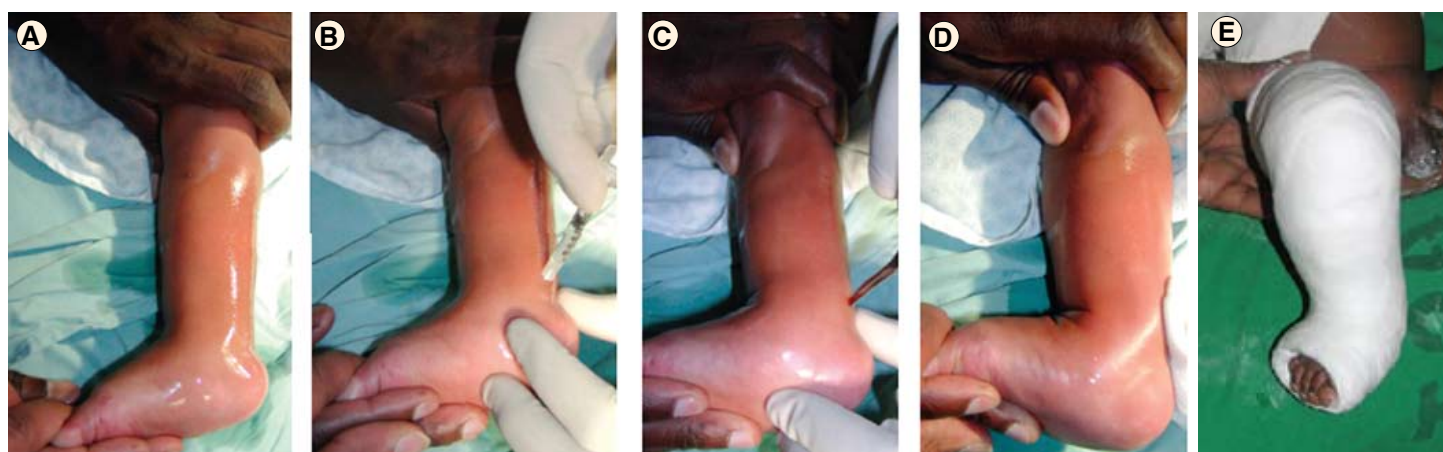
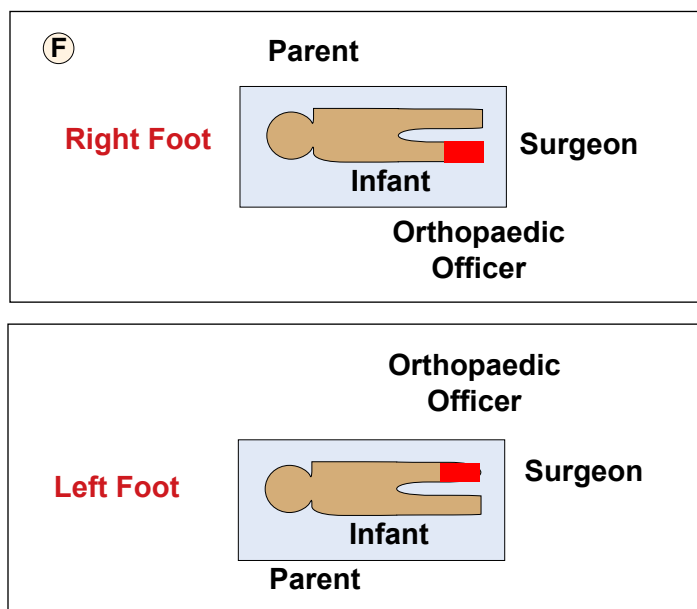
A small amount of bleeding is normal. A piece of clean gauze is placed over the incision and the orthopaedic officer applies a new above-knee plaster cast [E].

Post-tenotomy cast

After correction of equinus by tenotomy, apply the fifth cast [E and F] with the foot abducted 60 to 70 degrees with respect to the frontal plane of the ankle, and 15 degrees dorsiflexion. The foot looks overcorrected with respect to the thigh. This cast holds the foot for 3 weeks after complete correction. It should be replaced if it softens or becomes soiled before 3 weeks. The baby and mother may go home immediately. Usually no analgesic is necessary. This is usually the last cast required in the treatment program.

Cast removal

After 3 weeks, the cast is removed. Twenty degrees of dorsiflexion is now possible. The operative scar is minimal. The foot is ready for bracing. The foot appears to be overcorrected into abduction. This is often a concern to the caregiver. Explain that this is not an overcorrection, only full abduction.

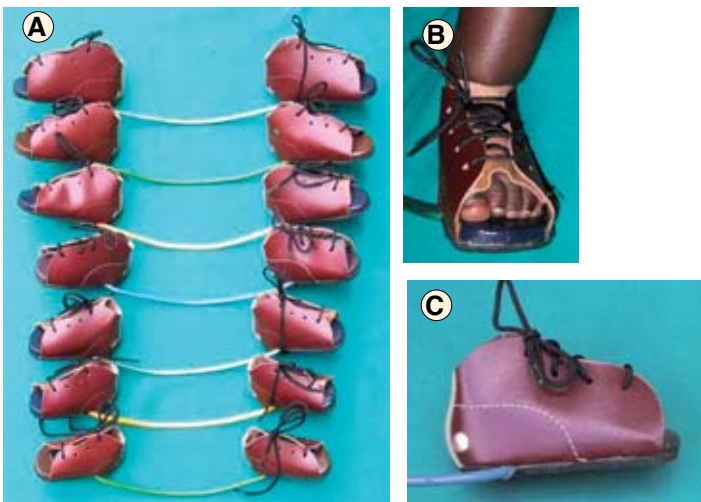


Bracing

Bracing is indispensable in preventing relapse. Even after full initial correction of the clubfoot, relapse is common. Relapse leads to disability. Prevent relapse by bracing the foot in the fully corrected position achieved in the last cast (foot abducted 70 degrees and dorsiflexed 15 degrees). Many braces have been tried. No brace works unless the foot is held abducted and dorsiflexed – hence the term *foot abduction brace*.

Steenbeek Foot Abduction Brace

Commercially available foot abduction braces (such as the Markell or Mitchell Brace) are expensive and difficult to access. In Uganda, use the Steenbeek foot abduction brace (SFAB). Developed by Michiel Steenbeek, working for the Christoffel Blinden Mission at the Katalemwa Cheshire Home in Kampala, the SFAB can be made from simple, easily available materials in Uganda. It is designed to be effective in maintaining correction, easy to use, easy to fabricate, inexpensive, and ideally suited for widespread use. SFABs are manufactured in standard sizes to fit all feet needing braces [A]. Standardized patterns allow prefabrication and bulk production. This enables the clinician to fit braces off the shelf [D].



SFAB Design Features

The SFAB has open toe leather shoes with lace closures [B]. A round iron bar connects the shoes. A hole in the heel allows checking the position of the heel [C]. Shoe abduction and dorsiflexion can be changed by bending the bar [E].

Standard sizes

SFABs come in eight standard sizes. Mass production [next page, A] means off-the-shelf availability. Each standard size has an appropriate length of bar between the shoes [A]. The length of the foot abduction bar is such that the distance from the inside of one shoe-heel to the other shoe-heel equals the width of the child's shoulders (measured at the lateral side of both deltoid muscles).

Inspection hole

The medial side of each shoe has an inspection hole to check the position of the heel in the shoe [C].

Deep heel cup

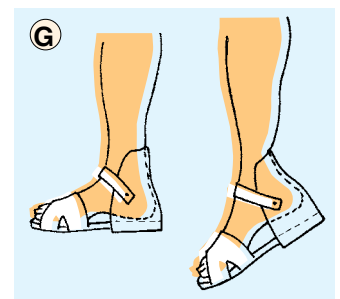
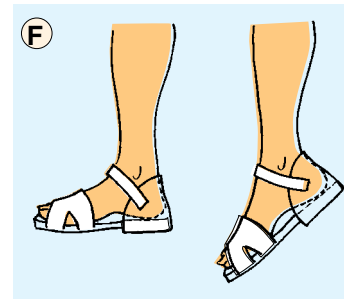
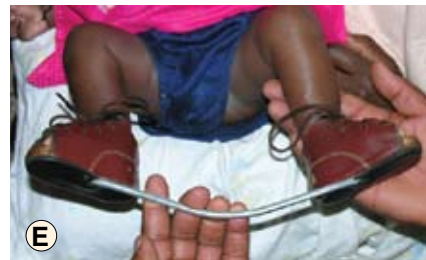The SFAB has a deep heel cup [C] designed to prevent the foot from slipping out of the shoe. It also promotes the soft tissues of the heel to develop into a normal shape.

Low heel cut design

The heel leather has a low posterior cut design [C] to prevent the heel from slipping out of the shoe.

If the heel leather of the shoe is low (at the level or below the level of the anatomical ankle joint) in plantar flexion, the heel of the foot remains well positioned on the sole of the shoe [F].

In contrast, if the heel leather is increased in size and it reaches above the anatomical ankle joint, a point of contact between the posterior side of the leg and the heel leather will now act as a fulcrum proximal to the anatomical ankle joint. The fulcrum causes the heel to lift up from the shoe when the child attempts to plantarflex the ankle [G].



SFAB Manufacture

The SFAB is critical for the success of a Ponseti treatment program in Uganda.

Materials and tools

Brace manufacture requires only local materials (leather, lining, plywood, and mild steel rod stock), ordinary shoe-making tools (a leather-sewing machine), and tools for metalworking and welding [C,E, and F].

Sustainability

Affordable local manufacture promotes sustainable brace supplies in Uganda.

Training The Orthopedic Technology School in Kampala includes fabrication of this brace in its curriculum. Each student is required to create 15 braces during training. Samuel Kayondo and David Kisombo tutor at the school [D].

Cost The SFAB is inexpensive when made in Uganda (about US \$7 in 2006).

Sources of Braces

Michiel Steenbeek at Katalemwa Cheshire Home and Rehabilitation Centre, Gayaza Rd, Mpererwe Market, Kampala or CBM [B].

Mulago Orthopaedic Workshop, Kampala [A].

Kumi General Hospital, Kumi.

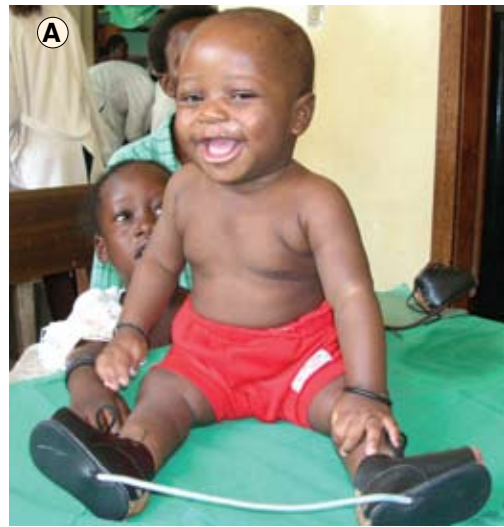
The Steenbeek brace production manual, in full color with patterns for all brace sizes, is available on www.global-help.org or by contacting michiel.steenbeek@lycos.nl or m.steenbeek@africaonline.co.ug.



38 Bracing

SFAB Availability

Stock SFABs in the clubfoot clinic so that they are available for immediate initial fitting and replacement. This will reduce relapse rates, and transport costs for the families of children with treated clubfeet.



Foot Size [cm]	Brace Size
6.5 to 7.5 cm	6
7.5 to 8 cm	7
8 cm	8
9 cm	9
10 cm	10
11 cm	11
12 cm	12
13 cm	13

First Bracing Visit

Apply the SFAB immediately after the last cast is removed, three weeks after tenotomy. Instruct caregivers that the brace is to be worn full time (except for bathing) for 3 months. Then it should be worn at night and nap time until the child is 4 years old [A].

Check shoe abduction and extension

SFABs are made with both shoes abducted 70 degrees and extended 15 degrees. Check this is so, especially if reusing a SFAB. Adjust as necessary.

Unilateral deformity

With a unilateral deformity, bend the bar next to the shoe for the normal foot back to 30–40 degrees abduction only.

Sizing

Measure the length of the sole of the child's clubfoot – once corrected – in centimeters from the heel to the tip of the big toe. In general this length in centimeters corresponds with the size of the SFAB needed. Do not add an allowance for growth. Select the correct size of the brace [B and C] from a full stock of all brace sizes kept in the clinic.

Fitting technique

Steenbeek has listed the important steps when first applying the brace to the infant's foot. These steps should be taught to the mother and family members [D]. It is important to have the mother demonstrate in the clinic that she can apply the brace correctly before leaving.

Make sure the ankle has at least 10 degrees dorsiflexion. Without enough dorsiflexion, the heel will tend to pull away from the heel cup, increasing the probability of the foot pulling out of the SFAB.

D

Steps in Brace Fitting [Facing page A, B, C]

1. Loosen and remove the laces from the shoes.
2. Fit the most difficult foot first. In unilateral cases, this is the involved foot; in bilateral cases it is the most rigid foot.
3. Gently push the foot up in dorsiflexion with one hand and hold that position, then push the foot, heel first, into the brace.
4. Close the tongue of the shoe and check through the inspection window to be certain that the heel is down in the brace.
5. While maintaining this position with one hand, lace the shoe with the other hand.
6. Fit the other foot in the brace the same way.
7. If the child cries more than usual, check the feet for red spots or blisters. In such a case, the brace might be too small for the child.
8. When the child is about to outgrow the SFAB, have the parents go back to the clinic or workshop for a larger size.

Follow-up Bracing Visits

Follow-up at regular intervals is essential to minimize bracing problems and to detect relapse early.

Visit schedule

At 2 weeks check for fitting problems and compliance.

At 3 months advance to nighttime use if no evidence of relapse. A new brace may be necessary.

Every 3 months until age 2 years and then every 6 months until 4 years of age.

Check SFAB fit and progress to a larger size as needed.

Inquire about home situation and brace use problems to identify problems that might lead to noncompliance.

Check for relapse as shown on page 42.

When to discontinue bracing

The SFAB can be discontinued after age of 4 years if there is no sign of relapse. See the child again after 6 to 12 months to be certain there is no relapse (about 5% of feet may relapse after 4 years of age).

If you notice any signs of relapse, reapply a series of corrective casts.

Improving SFAB Compliance

Frequently, caregivers will want to stop putting the SFAB on the child's feet because the feet look corrected and the child fusses. Failure to comply with bracing protocols is the most common cause of relapse. Explain to the parents making the following points:

Parent education

Explain the importance of the brace to the parents. Remind them often of the almost universal tendency for deformity to recur if the brace is not worn. Teach parents to exercise the child's knees together as a unit (flex and extend) in the brace, so that the child gets accustomed to moving two legs simultaneously. (If the child tries to kick one leg at a time, the brace bar interferes, and the child may get frustrated.)

Fit the SFAB immediately

The child will not have a chance to get used to having the feet free and will cry less if braces are fitted on the day the last casts are removed.

Demonstrate brace use

Ask the parent to apply the brace during the first visit to make certain the parents understand its use and application.

Reassure parents

Reassure parents that although there may be a few rough nights at first, the child will get accustomed to the brace. If the child cries more than usual, the parents can check the feet for red spots or blisters in case the brace might be getting too small for the child. If the foot appears satisfactory, the parents can reapply the brace and should check the child for other causes of pain such as earache.

Plan for growth

When the child is about to outgrow the brace, the parents and child should go back to the clinic/workshop for a bigger size.

Encourage consistency

Inform parents that regular brace use (every day) will make for a compliant child. Intermittent usage will make for a child who fights the brace.



Common Management Errors

The following are common management errors. Understand and avoid them. Your patients will have less trouble.

Errors before manipulation

Failure to recognize clubfoot, or refer to the clinic is a result of healthcare workers' lack of awareness of the clinical features of clubfoot or knowledge that it can be treated. Encourage healthcare workers to take all opportunities to perform a visual foot inspection, and if concerned, refer to the clubfoot clinic.

Failure to provide a holistic approach to the child and family Continually monitor how the family is dealing with the extra demands placed on them. Emphasize that the condition is totally correctable but requires the ongoing effort of the whole family. This helps families overcome the barriers they face in adhering to treatment protocols.

Starting casting without the family understanding the overall management plan Make certain the family understands the overall plan of management so they can plan. Explain that bracing is just as important as casting for success and that a common reason for failure is the premature discontinuation of bracing. Inform the family that the best way to prevent relapse is to use the SFAB as instructed until age 4 years. Families who understand the whole management sequence can avoid many problems.

Changing the management protocol described by Ponseti Avoid the common tendency to change treatment. Dr. Ponseti has carefully developed the technique over a period of 50 years.

Errors during manipulation

Failure to manipulate Manipulate the foot to place contracted ligaments at maximum stretch in the cast. In the cast, the ligaments loosen, allowing more stretching at the next session.

Manipulating without accurately identifying the head of the talus This error is commonly due to inexperience. To identify the head of the talus, palpate the lateral malleolus with the thumb [A]. Then move the thumb just forward to identify the next bony prominence – the head of the talus [B]. Successful correction of deformity depends of abduction of the calcaneus under the talus. This is impeded without counterpressure on the head of the talus.

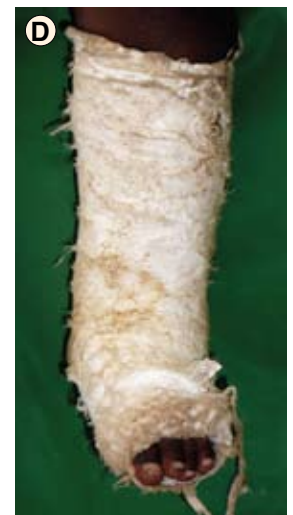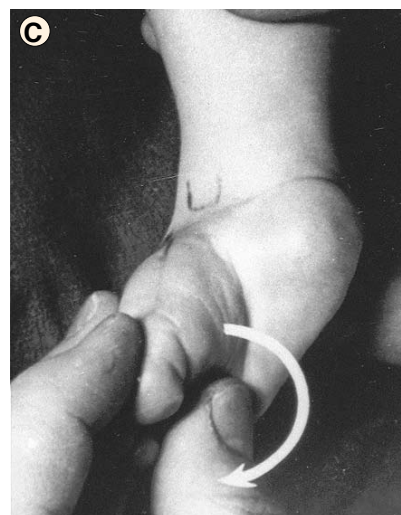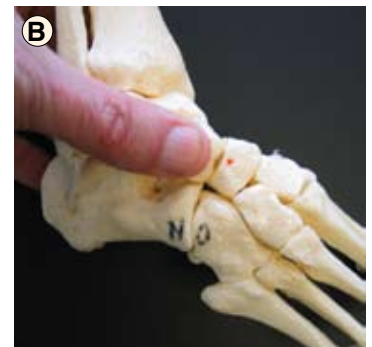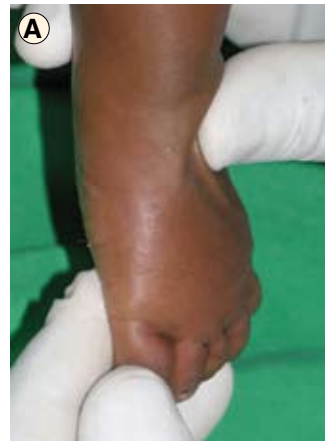Pronation of the foot This worsens the deformity by increasing the cavus. Pronation [C] does nothing to abduct the adducted and inverted calcaneus, which remains locked under the talus. Thou shalt not pronate!

Errors during casting

Failure to cast Performing frequent manipulations and not casting is an error. The foot should be casted with the contracted ligaments at the maximum stretch obtained after each manipulation. The stretched ligaments loosen sufficiently to facilitate further stretching at the next manipulation.

Using below-knee casts Below-knee casts do not hold the calcaneus abducted [D]. Above-knee casts are needed to prevent the ankle and talus from rotating within the cast; otherwise, the correction obtained by manipulation is lost.

Attempting to apply the cast alone without help Large clinics and limited personnel make it tempting to try casting without help. This only jeopardizes the correction by introducing the possibility of immobilizing the foot in an incorrect position. It is preferable to have a parent instructed how to hold the foot during the application than to apply the cast alone.



Errors during tenotomy

Premature equinus correction Attempts to correct the equinus before the heel varus and foot supination are corrected will result in a rocker-bottom deformity. Equinus through the subtalar joint can be corrected only if the calcaneus abducts. Tenotomy is indicated after cavus, adductus, and varus are fully corrected.

Failure to perform a complete tenotomy The sudden lengthening with a “pop or snap” signals a complete tenotomy. Failure to achieve this may indicate an incomplete tenotomy. Repeat the tenotomy maneuver to ensure a complete tenotomy if there is no “pop or snap.”

Errors during bracing

Ponseti management calls for bracing into foot abduction and ankle extension – the foot is placed in the fully corrected position, similar to the last cast. Bracing into pronation, eversion or external rotation does not do this. These were common errors before Ponseti management was taught.

Using braces other than the SFAB

An ankle foot orthosis (AFO) is like a below-knee cast [A]. It controls ankle extension but cannot maintain the calcaneus abducted under the talus, and the foot is not placed into the fully corrected position. In an AFO, the deformity is likely to recur.

The knee-ankle-foot-orthosis controls for foot abduction, but is inefficient at controlling for ankle extension. Because it keeps the knee in a permanent 90-degree flexion position, it does not stretch the gastrocnemius muscle satisfactorily. When the child starts standing with the knee extended and then walking, the foot will have an equinus contracture.

Failure to examine the foot for relapse during follow-up visits for bracing Identify relapse early by observing the child’s gait. In the stance phase of the normal gait cycle, the foot contacts the ground with the heel first (heelstrike), followed by the whole foot (flatfoot) and finally the toe leaves the ground (toe off).

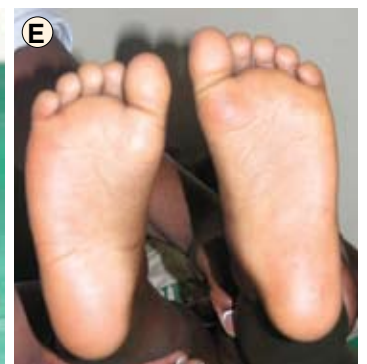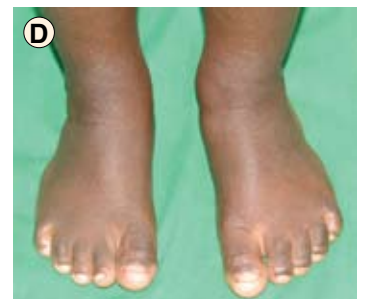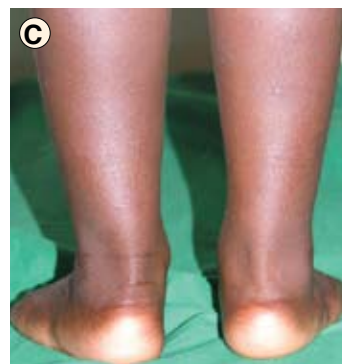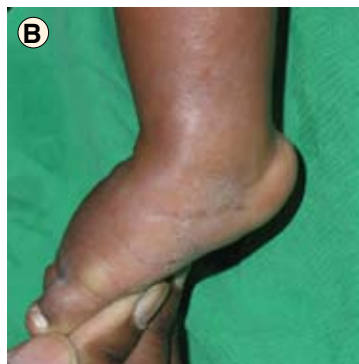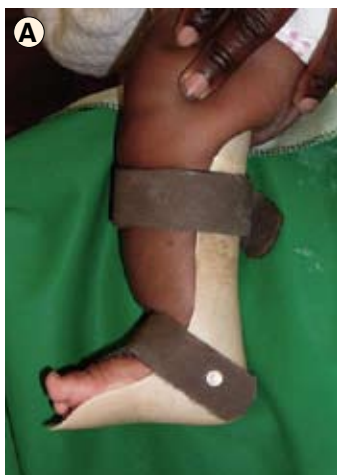Signs of early relapse are early heel rise (child walking away from examiner), swing phase dynamic supination (child walking towards examiner) and loss of ankle dorsiflexion to less than ten degrees [B].

Manage relapses by repeated corrective casting.

Management without bracing Avoiding the brace entirely is tempting as bracing can be difficult for the caregiver. However, studies have shown 90% relapse rates at 12 months of age if the brace is omitted. Bracing until 4 years of age is necessary to reduce risk for relapse. Relapse is rare after age four.

Attempts to obtain perfect anatomical correction

It is wrong to assume that Ponseti treatment will result in completely normal anatomy. For example, complete reduction of the extreme medial displacement of the navicular may not be possible. Long-term follow-up radiographs show some abnormalities. There is no correlation between the radiographic and clinical appearance of the foot. Good long-term function of the Ponseti-treated clubfoot can be expected, as long as the foot is supple and plantigrade. A well treated right clubfoot and a normal left foot are shown [C, D, and E]. Note the small differences between the feet. Although anatomically imperfect, correction will provide good functional and cosmetic results for at least five decades. This avoids many of the complications of operative tarsal release, such as stiffness and pain.



Relapse

Relapse

Ponseti management corrects deformity, but it does not remove the cause of clubfoot. It has a stubborn tendency to recur.

Causes

Relapse is almost always due to failure or incorrect brace wear. Morcuende (2003) found that relapses occur in only 6% of compliant families but more than 80% of noncompliant families. The importance of the brace must be explained to the parents.

With growth, the tendency for relapse lessens considerably: 91% of relapses occur before 5 years of age. Relapse after age 7 is very rare. It may be an indicator of an underlying neuromuscular disorder.

Sequence and early identification

Relapse has a characteristic sequence. Early relapse presents as a loss of dorsiflexion. Later, heel varus and adductus develop. Rarely is significant cavus a feature. Early relapse is therefore easier to correct than late relapse. Detection of early relapse is important. At every clinic visit, look for relapse.

History

Ask parents about bracing difficulties (pain, inconsolable crying, sore areas,) that may have led to inconsistent use. Parents may have noted the heel not touching down on the footplate of the shoe.

Age

The signs of relapse before walking and after walking age are different.

Signs Before Walking Age

Examine the child seated on the mother's lap – look for:

Brace usage

The brace should look well used. Check the angle of abduction and dorsiflexion – parents sometimes bend the bar into an ineffective angle.

Loss of passive ankle dorsiflexion

This should be at least 10 degrees above neutral with the knee extended [A]. Recognize early relapse if dorsiflexion is any less, even in the presence of full subtalar motion [B].

Palpable head of talus

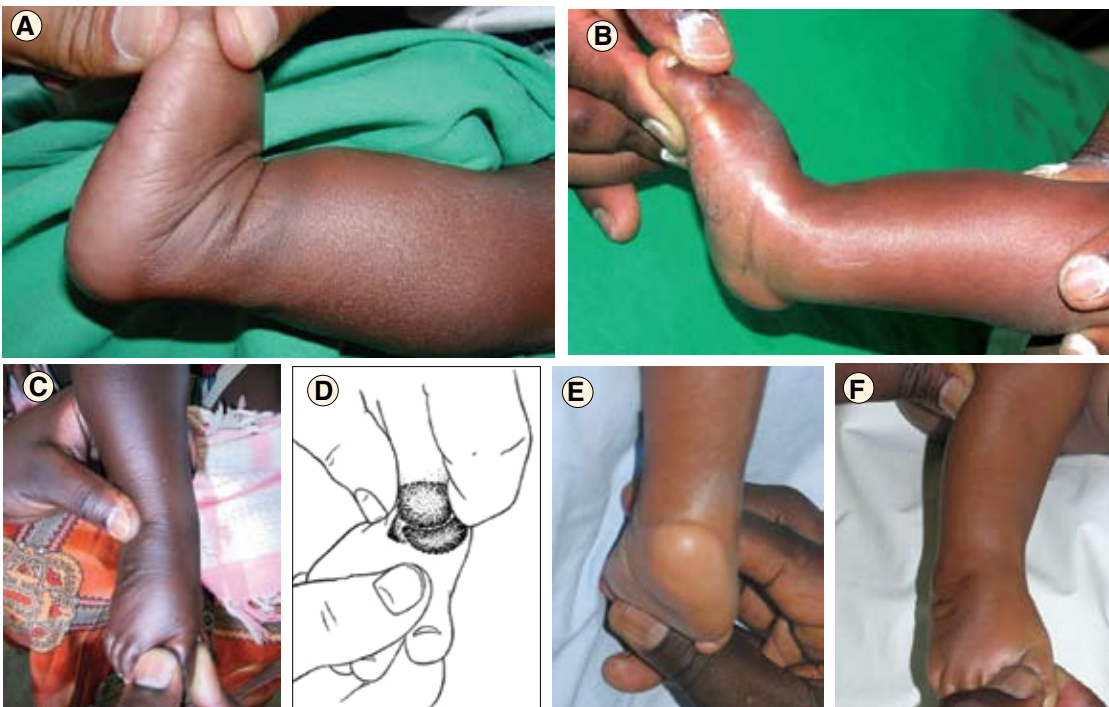
Abduct the foot with counterpressure on the head of the talus [C]. The navicular should cover the talar head completely. Recognize late relapse if the talar head remains palpable with the foot in maximal available abduction [D]. The navicular and anterior tuberosity of the calcaneus cannot be abducted.

Loss of calcaneal abduction and extension

With late relapse, foot abduction is insufficient. Therefore, the heel will not go into valgus and the calcaneus will not extend [E and F].

Supination

Involuntary supination of the foot during active ankle dorsiflexion often represents tibialis anterior activity unopposed by weak peroneals.



Signs After Walking Age

Observe the child's feet standing. Then ask the child to walk towards and away from you. Repeat as needed. Observe what the foot does in swing and stance phases of gait. Then examine the child's foot with the child on mother's lap.

Standing and walking

Standing Look at how the foot weight-bears or touches the ground. In early relapse, the foot appears planigrade. However, the heel may not touch the ground [C]. Additionally, in late relapse, the medial forefoot is raised off the ground [A, left foot], or the foot bears weight on the lateral border [B].

Walking Early relapse is most easily appreciated as the child walks away from you as early heel rise. Late relapse is seen as the foot tending to supinate in swing phase (dynamic supination), and as weight bearing on the lateral rays of the foot (child walking towards you) [A, left foot; B]. Heel-strike is absent, and there is fixed stance-phase heel varus (child walking away from you) [D].

Examine the child seated on the mother's lap

Passively test ankle and subtalar joint range of motion. Recognize early relapse if ankle dorsiflexion is less than 10 degrees above neutral with the knee extended [E]. Subtalar joint involvement (seen as a loss of full calcaneal abduction or incomplete talar head coverage by the navicular) indicates late relapse [F and G].

Active ankle dorsiflexion may be accompanied by supination of the foot from tibialis anterior overactivity.

Sole of foot may show thickening of the skin under the lateral rays.

Treatment of Relapse

Do not ignore relapse. Treat at the first sign. Delaying treatment only results in more relapse. Early relapse is much easier and less complicated to deal with than late relapse.

Relapse before 30 months of age

Treat with repeat manipulation and casting, adding tenotomy if needed.

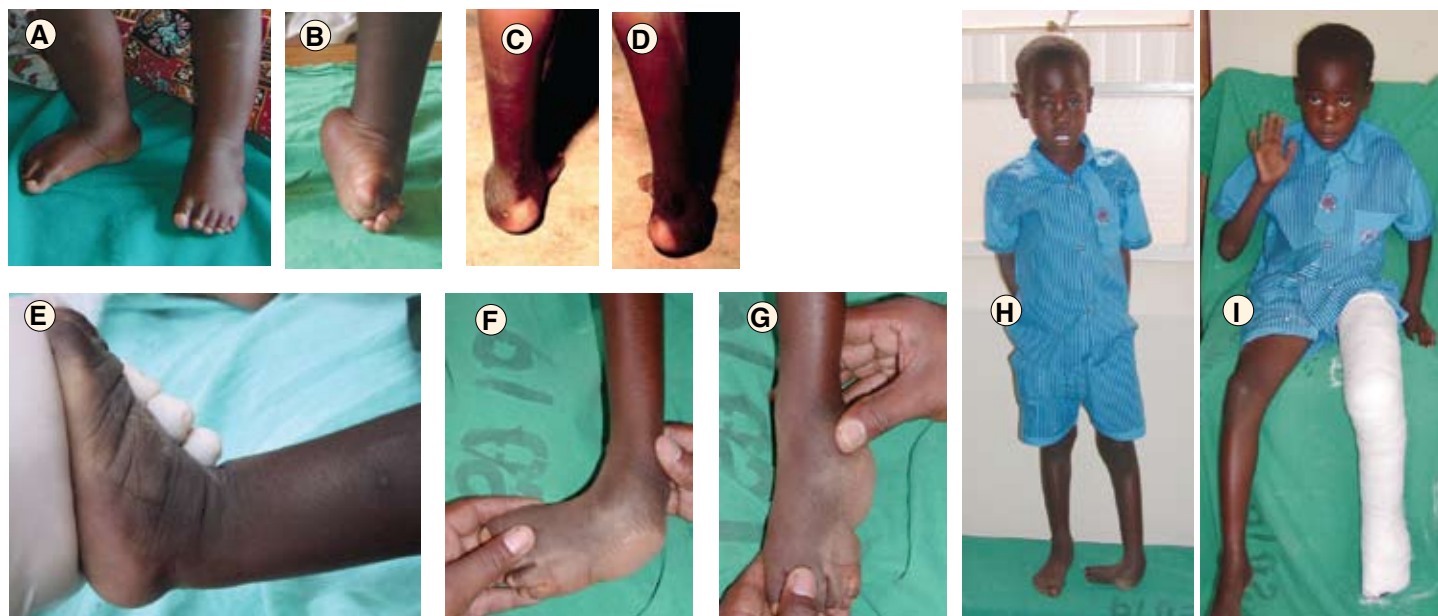
Manipulate and cast one to three times at 2-week intervals [H and I] until the foot is completely corrected. Use the technique as shown on pages 28 to 31.

Tenotomy can be repeated if ankle dorsiflexion is less than 10 degrees above neutral after the third cast. Apply a fourth cast for 3 weeks. No significant problems have been associated with repeat tenotomies.

Bracing remains critical to prevent further relapse. Restart bracing after understanding the caregiver's barriers to bracing. Come up with a strategy that will resolve the problem.

Relapse after 30 months of age

Treat a child's first relapse after 30 months of age as above. A second or subsequent relapse is an indication for transfer of the tibialis anterior to the lateral cuneiform. Its ossification center usually appears at 30 months of age and can act as a suitable attachment site for a tendon transfer. Changing the attachment point from the medial side of the foot to the dorsum turns the deforming force of the tibialis anterior into a corrective force. First manipulate and cast to correct deformity [H and I]. Then refer to the surgeon for anterior tibialis tendon transfer.



Anterior Tibialis Tendon Transfer

Indication

Transfer is indicated if the child is more than 30 months of age and has a second relapse. Indications include persistent heel varus and forefoot supination during walking; the sole shows thickening of the lateral plantar skin.

Correct deformity

Make certain that any fixed deformity is corrected by two or three casts before performing the transfer [next page, G and H]. Usually cavus, adductus, and varus corrects. Equinus may be resistant. If the foot easily dorsiflexes to 10 degrees, only the transfer is needed. Otherwise add tenotomy of the heelcord.

Anaesthesia, positioning and incisions

Put the patient under a general anaesthetic, positioned supine. Use a high-thigh tourniquet. Make a dorsolateral incision centered on the lateral cuneiform. Its surface marking is the intersection of two lines (base of the fifth metatarsal to cunieform–first metatarsal joint and proximal projection of third metatarsal) [A]. The dorsomedial incision is made over the insertion of the anterior tibialis tendon [B].

Expose anterior tibialis tendon

Expose the tendon and detach at its insertion [C]. Avoid extending the dissection too far distally to avoid injury to the growth plate of the first metatarsal.

Place anchoring sutures

Place a #0 dissolving anchoring suture [D]. Make multiple passes through the tendon to obtain secure fixation.

Transfer the tendon

Transfer the tendon to the dorsolateral incision [E]. The tendon remains under the extensor retinaculum and the extensor tendons. Free the subcutaneous tissue to allow the tendon a direct course laterally.

Localize lateral cuneiform

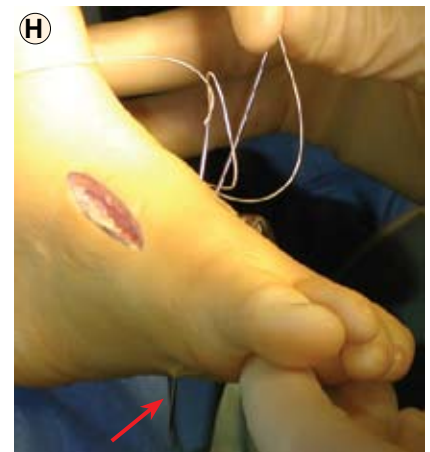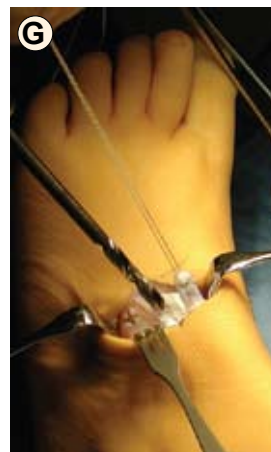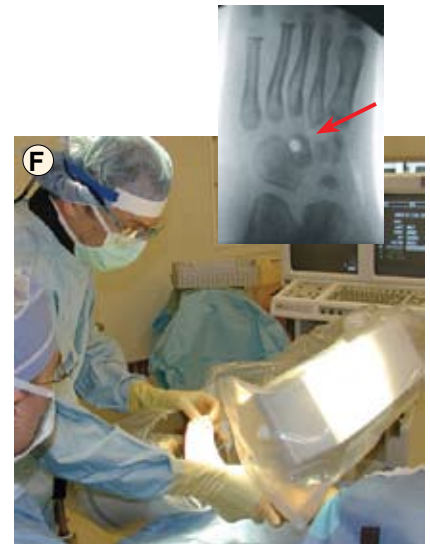
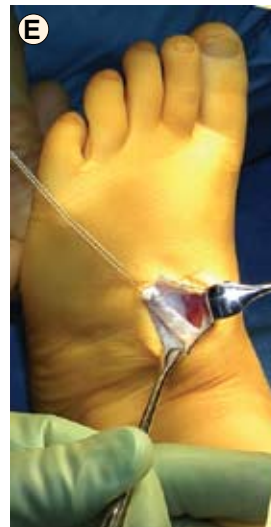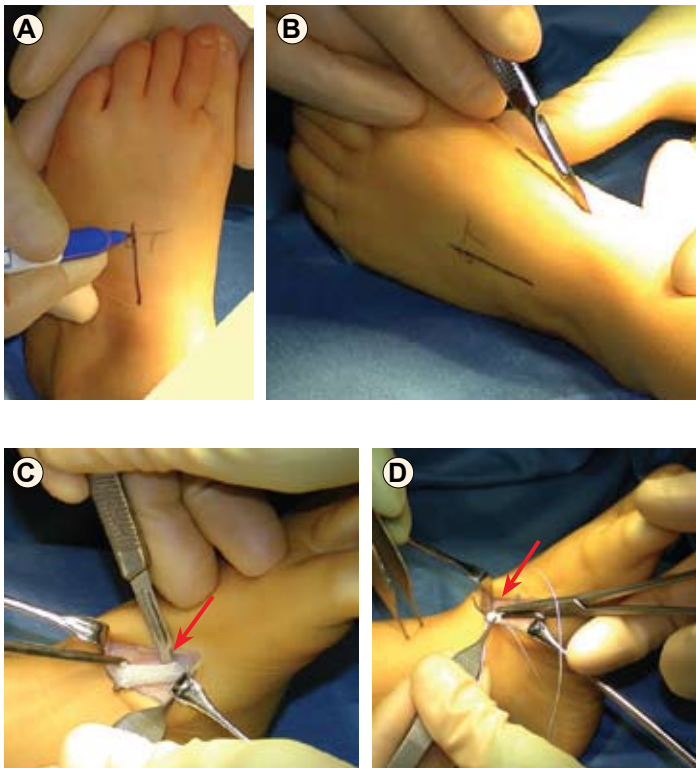
If available, use x-ray [F]. Note the position of the hole in the radiograph [F, inset arrow]. Otherwise identify by delineating the joint between it and the third metatarsal.

Identify site for transfer

Make a drill hole in the middle of the lateral cuneiform large enough to accommodate the tendon [G].

Thread sutures

Thread a straight needle on each of the securing sutures. Pass one needle into the hole. Leave the first needle in the hole while passing the second needle to avoid piercing the first suture [H]. Note that the needle penetrates the sole of the foot [H, arrow].



Pass two needles

Place the needles through a felt pad and then through different holes in the button to secure the tendon [A].

Secure tendon

With the foot held in dorsiflexion, pull the tendon into the drill hole [B, arrow] by traction on the fixation sutures and tie the fixation suture with multiple knots [D, arrow].

Supplemental fixation

Supplement the button fixation by suturing the tendon to the periosteum at the site where the tendon enters the cuneiform [C, arrow], using a heavy absorbable suture.

Neutral position without support

Without support, the foot should rest in neutral plantar flexion [D] and neutral valgus-varus.

Local anesthetic

Inject a long-acting local anesthetic into the wound [E] to reduce immediate postoperative pain.

Skin closure

Close the incisions with absorbable subcutaneous sutures [F]. Tape strips reinforce the closure.

Cast immobilization

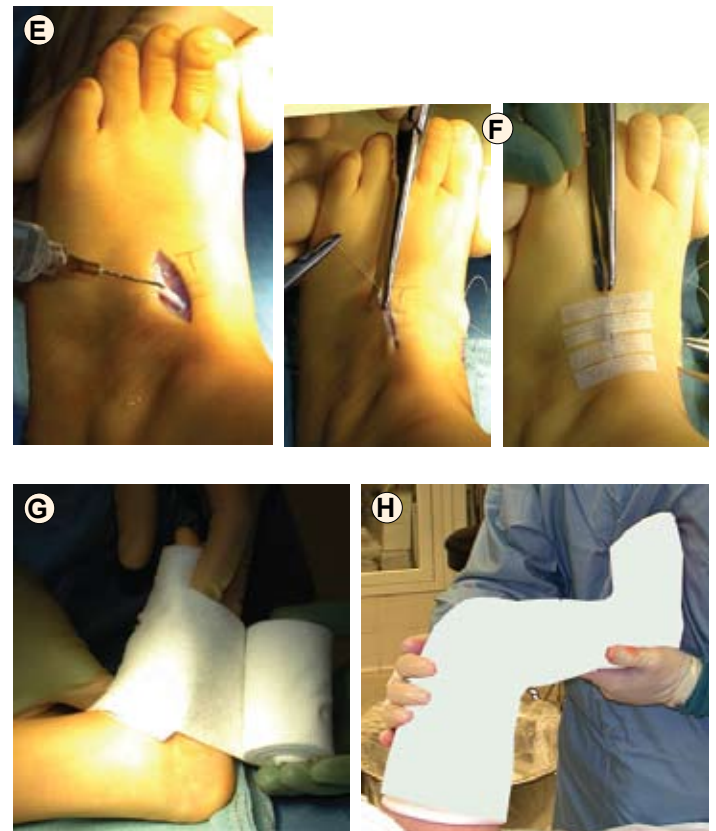
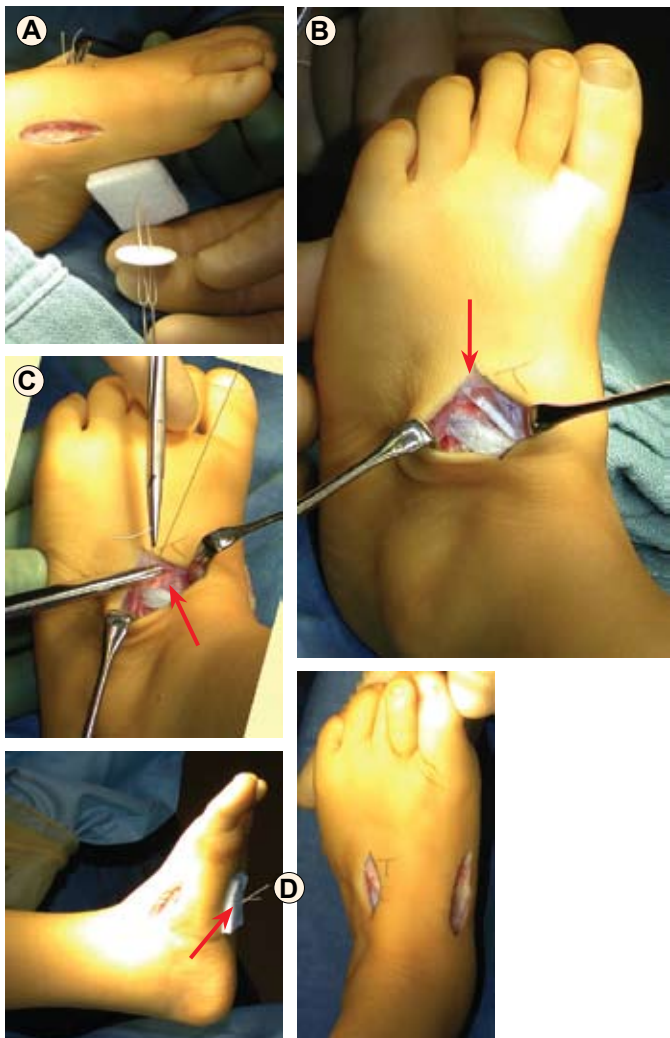
Place a sterile dressing [G], and apply a long-leg cast [H]. Keep the foot abducted and dorsiflexed.

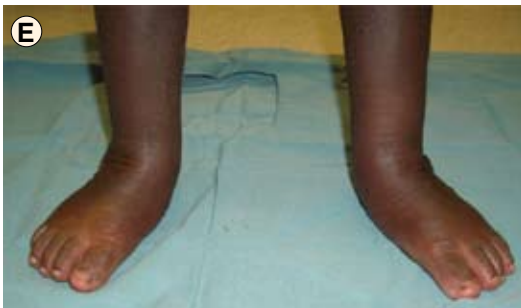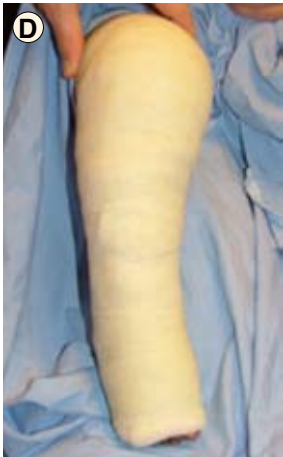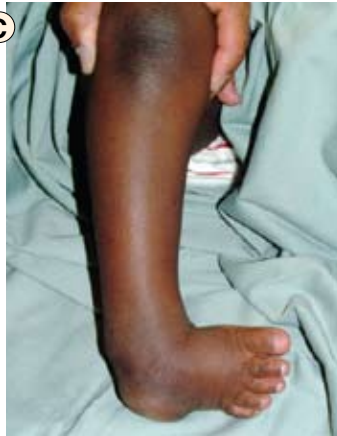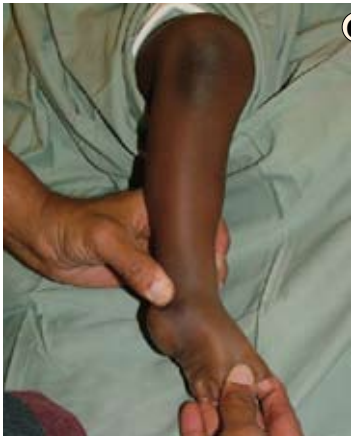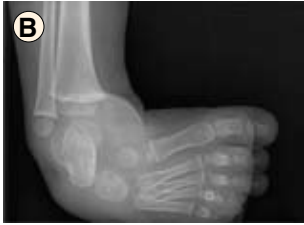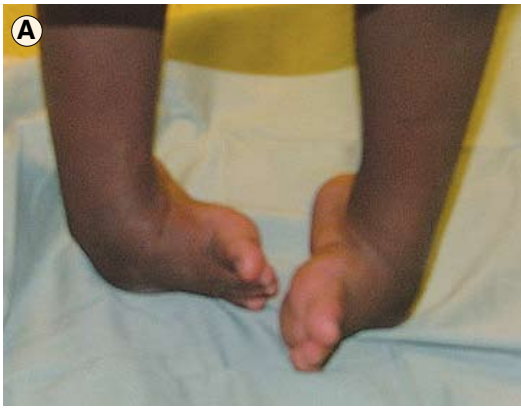Postoperative care

Usually, the patient remains hospitalized overnight. The sutures absorb. Remove the cast and button at 6 weeks. The child may mobilize weight-bearing as tolerated.

Bracing and follow-up

No bracing is necessary after the procedure. See the child again in 6 months to assess the effect of the transfer.





Difficult Clubfeet

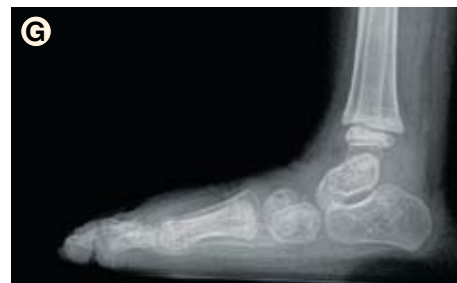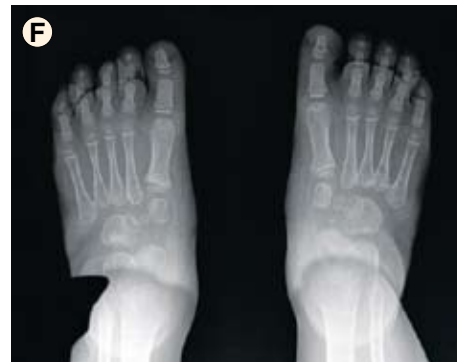Most idiopathic congenital clubfeet correct with about five well-applied Ponseti casts. Some clubfeet, however, can be considered “difficult” as they have some unique characteristics that demand a modified approach for management.

The untreated clubfoot in the older child

Treatment This 3-year-old with severe deformity [A] and x-rays [B] had no prior treatment. The feet were managed with six manipulations [C] and casts [D]. This was followed by a tenotomy and a holding cast maintained for 6 weeks. Following treatment, the foot was clinically well corrected [E]. Radiographs [F and G] showed marked improvement.

Results In Nepal, 79 clubfeet in children aged 1–5 years were treated as described above. Treatment resulted in plantigrade feet in all cases.

Upper age limit Experience from the developing world suggests that the Ponseti Method continues to be effective well after walking age. However it is likely that beyond 3 years of age there will be increasing residual deformity. Further treatment may be necessary for residual deformity, such as a calcaneo-cuboid fusion for residual calcaneo-cuboid subluxation.



The complex congenital clubfoot

The complex congenital clubfoot, a recently described variant of congenital clubfoot, is important to recognize. Treatment needs to be modified. There is an increased risk of relapse.

History There is often a history of casts slipping so that toes slowly disappear inside the plaster.

Exam The signs of the complex clubfoot are rigid equinus, plantaris (severe plantarflexion of all metatarsals), a deep crease just above the heel, a deep transverse crease across the sole of the midfoot, a short hyperextended big toe, abnormal “flattened” shape to heel [A, B] and an edematous dorsum of the foot. If present, consider modifying the treatment.

Modify treatment Using the classic Ponseti Method results in development of a secondary deformity. (The forefoot adduction corrects with first or second cast. Cavus however persists. Further attempts to abduct the forefoot cause an increase in plantaris and abduction of metatarsals at the lizfranc joint rather than abduction of calcaneus.) A modification of the management technique is needed to prevent this.

Manipulation Carefully identify the talar head laterally. It is not as prominent as the anterior process of the calcaneus. When manipulating, the index finger should rest over the posterior aspect of the lateral malleolus while the thumb of the same hand applies counterpressure over the lateral aspect of the talar head [E, lower picture]. Do not abduct more than 40 degrees. After 40-degree abduction is achieved, change emphasis to correction of plantaris. All metatarsals are extended simultaneously with both thumbs [E, upper picture].

Casting Always apply casts with the above-knee portion in 110 degrees flexion to prevent slippage. Up to ten casts can be needed to correct deformity.

Tenotomy A tenotomy is necessary in all cases. Perform the tenotomy when plantaris is corrected. At least 10 degrees dorsiflexion is necessary. Sometimes it is necessary to change casts at weekly intervals after the tenotomy to gain more dorsiflexion, if sufficient dorsiflexion is not achieved immediately after the tenotomy.

Bracing Reduce abduction on the affected side to 40 degrees in the foot abduction brace. The follow-up protocol remains the same.

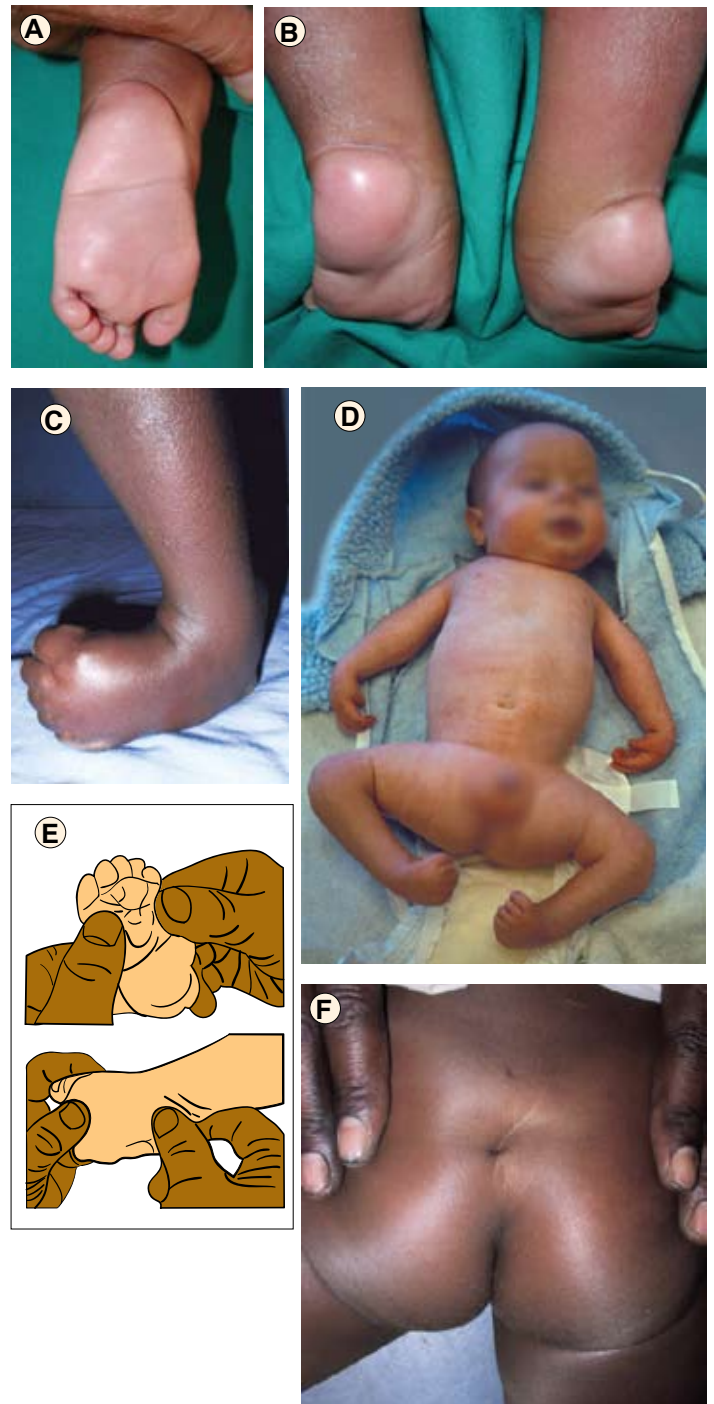
The clubfoot in a child with a syndrome

Children with clubfeet seen in the presence of other congenital abnormalities, such as arthrogyriposis [C and D], myelomeningocele [F], and other syndromes, often have abnormal collagen forming their ligaments, capsules, and other soft tissues. Syndromic clubfeet have been difficult to treat in the past, and often have required surgery.

Experience with the Ponseti Method Many if not most syndromic clubfeet do correct. Therefore manage syndromic clubfeet initially with the standard Ponseti technique; however, be aware that correction may require more casts than usual. Usually a plantigrade foot can be obtained without surgery.

Long-term functional outcome usually depends more on the underlying syndrome than the clubfoot.

Resistant clubfoot Rarely, idiopathic congenital clubfeet do not correct completely with accurately applied Ponseti treatment. Sometimes there is co-existing pathology such as tarsal coalition. A posterior or posteromedial release may be necessary.




*I.V. Ponseti, M.D.
Division of Pediatric Orthopaedics
200 Hawkins Drive, 01025 JPP
Iowa City, IA 52242-1088
319-356-3469 Tel
319-353-7919 Fax*

This publication is a most welcome message to instruct parents and Ugandan healthcare students and providers to become acquainted with the clubfoot deformity and its treatment. The clubfoot, if not treated, is very crippling. With proper treatment, the clubfoot is functionally normal and painfree for life.

The steps for the detection and nonsurgical treatment of clubfoot are clearly outlined in this manual. Although written by Shafique Pirani, M.D. and Edward Naddumba, M.D., it has the backing of the Uganda Sustainable Clubfoot Care Project and the endorsement of Dr. Stephen Mallinga, Minister of Health of Uganda. I was very pleased to read with enthusiasm this publication and I know it will be a great asset in correcting the clubfoot deformity in patients in Uganda as well as many places throughout the world.

I. V. Ponseti

I. V. Ponseti, M.D.



ISBN 978-1-60189-050-4



9 781601 890504